

The Union

International Union Against
Tuberculosis and Lung Disease

DIAGNOSTIC CXR ATLAS FOR TUBERCULOSIS IN CHILDREN

A guide to chest X-ray interpretation

**Second Edition
2022**

DIAGNOSTIC CXR ATLAS FOR TUBERCULOSIS IN CHILDREN

A guide to chest X-ray interpretation

**Second Edition
2022**

Megan Palmer, James A. Seddon,
Pierre Goussard and H. Simon Schaaf

© International Union Against Tuberculosis and Lung Disease (The Union)
2 Rue Jean Lantier, 75001 Paris, France

Second edition, 2022

Copyright is retained by The Union. Individuals wishing to reproduce material from the Guide must request written permission from publications@theunion.org. Likewise, authors who wish to include material from other copyrighted sources must seek permission from the copyright holders and provide written evidence of this permission at the time their work is submitted.

This publication was supported by Cooperative Agreement Number NU2GGH002222 from the U.S. Centers for Disease Control and Prevention. Its contents are solely the responsibility of the authors and do not necessarily represent the official views of the U.S Centers for Disease Control and Prevention, the U.S Department of Health and Human Services, or the U.S government.

ISBN: 979-10-91287-32-6

Contents

	<u>Preface</u>	<u>5</u>
	<u>Authorship</u>	<u>6</u>
	<u>Acknowledgements</u>	<u>6</u>
	<u>Abbreviations and acronyms</u>	<u>7</u>
1	<u>Introduction</u>	<u>8</u>
2	<u>Role of the CXR in paediatric TB</u>	<u>11</u>
3	<u>CXR evaluation in children</u>	<u>13</u>
3.1	Basics of CXR interpretation	13
3.2	Assessing technical quality	13
3.3	Example of a systematic approach to paediatric CXR evaluation	18
3.4	Interpreting lateral CXR film	20
3.5	Effect of age	23
3.6	Effect of HIV infection	25
3.7	Sensitivity and specificity of different CXR features for paediatric TB	26
4	<u>Algorithmic approach to CXR evaluation in a child with presumptive pulmonary TB</u>	<u>27</u>
5	<u>The specific and less specific CXR features for paediatric TB</u>	<u>29</u>
5.1	The Normal CXR	31
5.2	CXR features which are very specific for paediatric TB	33
5.3	CXR features which are not very specific for paediatric TB	77
6	<u>Approach to assessing radiological disease severity on CXR in paediatric TB</u>	<u>86</u>
	<u>Glossary</u>	<u>90</u>

Preface

Despite substantial progress in the prevention and treatment of tuberculosis (TB) since the first edition of this publication in 2003, approximately 250,000 children are still dying from this curable disease every year. At the United Nations first-ever high-level meeting on TB in 2018, a global target was set to diagnose and treat 3.5 million children by 2022. However, annually fewer than half of the children estimated to develop TB are diagnosed and treated. It is clear that efforts to prevent TB deaths by diagnosing and treating TB in children must be urgently accelerated.

Chest X-rays (CXRs) are a critical component of the child TB diagnostic approach and yet, in many contexts, healthcare workers do not feel confident in their ability to interpret CXR images. This second edition of the 'Diagnostic CXR atlas for tuberculosis in children: a guide to chest X-ray interpretation' has been extensively revised and includes six sections. These describe the role of the CXR in diagnosing children with TB, introduce an algorithmic approach to CXR evaluation in a child with symptoms and signs of TB, present a comprehensive review of CXR features, including how specific they are for paediatric TB, and outline an approach to the classification of radiological disease severity on CXR in children treated for TB. The Atlas presents numerous CXR images with detailed annotations and summarises key messages to enhance its reader-friendliness.

The immediate beneficiaries of this Atlas are frontline healthcare workers in low- and middle-income settings, in both public and private health facilities, where sick children seek care. They include medical, clinical and nursing officers, paramedical staff, child health specialists, TB, HIV and child health focal people within programmes, TB and HIV coordinators, radiographers and X-ray technicians. The target audience of the Atlas includes also educators of these healthcare providers, supervisory level health officers, members of child TB working groups and national TB and child health programme managers and staff.

We hope that this Atlas will contribute to capacity and confidence building among healthcare workers who interpret CXRs from children. We believe that this is one way of ensuring that more children with TB are appropriately diagnosed and initiated on treatment.

Authorship

Desmond Tutu TB Centre, Department of Paediatrics and Child Health, Faculty of Medicine and Health Science, Stellenbosch University, Cape Town, South Africa (*Megan Palmer, James A. Seddon, Pierre Goussard, H. Simon Schaaf*)

Acknowledgements

If we have seen further, it is by standing on the shoulders of giants.

Professor Robert Gie authored the first edition of this Atlas and mentored the authors of this second edition. He trained a generation of TB researchers on many aspects of the clinical management of childhood TB and on TB research. He was passionate about the reading of CXRs and taught hundreds of students, doctors and researchers how to read CXRs and, perhaps more importantly, how to think critically about what the identified CXR features might mean. Professor Gie felt strongly that we should be teaching people about ALL the CXR patterns that we see in children with TB, and not just the perfect pictures. We hope that this edition of the Atlas does him justice.

We would also like to acknowledge the International Union Against Tuberculosis and Lung Disease (The Union) for supporting development of this publication and the following who reviewed it: *Riitta A. Dlodlo, Grania Brigden, Stephen M. Graham, Kobto G. Koura*

We thank the SHINE trial team and the Medical Research Council Clinical Trials Unit at University College London, UK, for contributing SHINE CXRs and developing the CXR infographics included in this publication, which were illustrated by Will Everett.

We also thankfully acknowledge the contributions of the following reviewers:

Sithabiso Dube (The Union Zimbabwe Trust, Zimbabwe), *Riana Greyling* (Western Cape Department of Health, South Africa), *Catherine Janari* (Western Cape Department of Health, South Africa), *Simba Mashizha* (National Tuberculosis Programme, Zimbabwe), *Isabelle Munyangaju* (Tinpswalo Association: Vincentia Association to Fight AIDS and TB, Mozambique), *Dulce Osorio* (Tinpswalo Association: Vincentia Association to Fight AIDS and TB, Mozambique), *Moorine P. Sekadde-Kasirye* (National TB and Leprosy Program, Uganda).

Abbreviations and acronyms

AP	Antero-posterior
ART	Antiretroviral therapy
CAD	Computer-aided detection
CXR	Chest X-ray
HIV	Human immunodeficiency virus
IGRA	Interferon-gamma release assay
LAM	Lipoarabinomannan
LIP	Lymphocytic interstitial pneumonia
<i>M.tb</i>	<i>Mycobacterium tuberculosis</i>
PA	Postero-anterior
PTB	Pulmonary tuberculosis
SHINE	Shorter treatment for minimal TB in children
TB	Tuberculosis
The Union	International Union Against Tuberculosis and Lung Disease
TST	Tuberculin skin test
TPT	TB preventive therapy
WHO	World Health Organization

1 Introduction

Children with pulmonary tuberculosis (TB) who are diagnosed early and access appropriate treatment have excellent clinical outcomes; and yet almost 250, 000 children die from children with TB globally each year. Modelling studies suggest that 95% of these children were not diagnosed at the time of death. To reduce TB-associated mortality in children we need to improve diagnostic strategies and facilitate early access to treatment.

The paediatric age group referred to in this Atlas includes children up to the age of 19 years. The disease spectrum across this age range is wide. Pulmonary TB represents the commonest TB manifestation in children. For the purposes of this Atlas, the term pulmonary TB is used interchangeably with the term intra-thoracic TB, and includes the involvement of the mediastinal lymph nodes as well as pleural involvement and miliary TB which are extra-pulmonary manifestations that can be diagnosed on the CXR.

TB in young children (<10 years) is usually paucibacillary (this means that there are few organisms) and microbiological confirmation rates for pulmonary TB, where sampling and testing is available, are only 10-30%. Although microbiological confirmation should always be attempted by collecting samples such as sputum, gastric aspirates, stool or urine most children with pulmonary TB are diagnosed clinically and the CXR is commonly used to support clinical decision-making.

This guide will outline approaches to support healthcare workers in resource-limited settings on how best to use the CXR to support the investigation of a child with presumed pulmonary TB.

This Atlas focuses on the interpretation of the CXR to support a diagnosis of pulmonary TB in a symptomatic child who has been brought to a healthcare facility in a low resource, high TB-burden setting.

Text Box 1.1: Pathogenesis of paediatric TB

Children usually develop TB after inhaling droplet nuclei containing *Mycobacterium tuberculosis* (*M. tb*) which have been coughed or breathed out by another person with infectious TB disease. This person is usually an adult or older child and can be called “the source case”. Droplet nuclei can remain in the air for several hours. When a child inhales these infected droplets the *M. tb*, or TB bacilli, may breach the innate immune system to reach the terminal alveoli where they multiply to form a parenchymal focus in the lung. This is called the primary focus or Ghon focus. The bacilli are then carried via the lymphatic system to the nearest mediastinal lymph node. The child may be asymptomatic or minimally symptomatic and the infection is usually contained by the immune system (with low numbers of TB bacilli persisting) or completely cleared. Children who have no symptoms and no radiological changes on CXR, but who may have a positive tuberculin skin test (TST) or interferon-gamma release assay (IGRA), are classified as having TB infection and do not have TB disease. These children should be considered for TB preventive treatment (TPT). However, if the bacilli overcome the constraints of the immune system and multiply, then there is progression to symptomatic TB disease which is accompanied by radiological changes on CXR (and which may involve other sites of disease). The radiological disease spectrum on CXR in children is wide and is broadly outlined in the Figure 1.1 below.

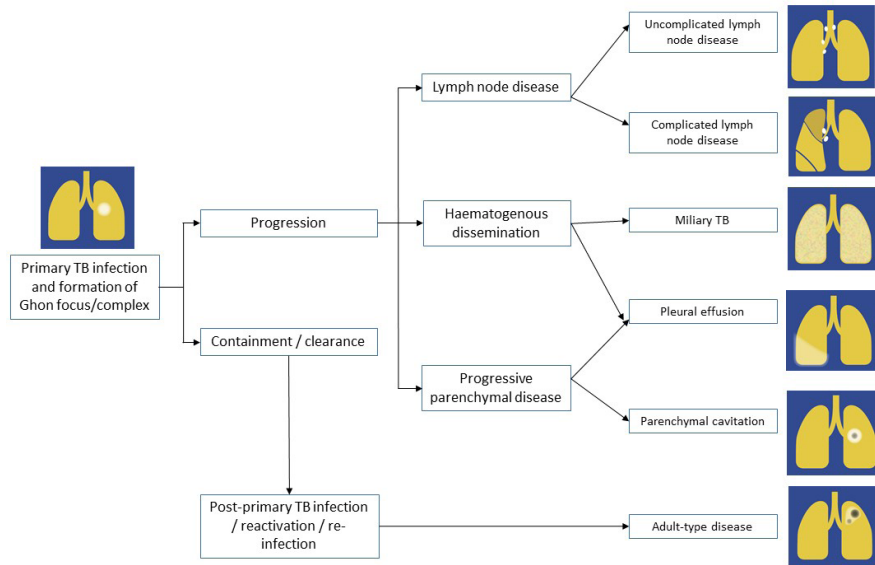


Figure 1.1: Schematic representation of the pathogenesis of paediatric TB

2 Role of CXR in paediatric TB

In the context of paediatric TB, the CXR may be useful in the following clinical scenarios:

- The evaluation of a symptomatic child with presumptive TB:
 - to decide whether to treat for TB disease or not.
 - to make a decision about TB disease severity and therefore which treatment regimen and duration to choose.
- The evaluation of a child, who may be asymptomatic, but who has been exposed to a TB source case:
 - to make a decision about starting TPT.

In this Atlas the focus is on the evaluation of a child who is brought to a health facility with symptoms and signs suggestive of pulmonary TB disease (a child with presumptive pulmonary TB) in a resource-limited, high TB-burden setting. The approach to CXR classification that is suggested in the following Sections will be less relevant in low TB-burden settings. The Atlas also focuses on the classification of radiological disease severity on CXR, as severity will increasingly impact on TB treatment regimen selection and/or duration.

This Atlas does not address the approach to the asymptomatic child who has been exposed to a TB source case or the role or interpretation of the CXR in the follow-up of a child on TB treatment.

Text Box 2.1: CXR in the context of diagnostic algorithms for paediatric TB

The CXR should not be interpreted in isolation. It should be evaluated as part of a broader diagnostic algorithm for paediatric TB disease which also includes the assessment of:

- Symptoms and signs suggestive of TB
- Exposure to a TB source case
- Results from tests for TB infection (TST or IGRA), if available
- Results from microbiological tests, such as XpertMTB/RIF, microscopy or culture for TB, if available
- Results from any other test supporting the diagnosis of TB, such as urinary lipoarabinomannan (LAM).

A comprehensive discussion of diagnostic algorithms for paediatric TB is beyond the scope of this Atlas. There are several systematic approaches that can be used and we refer the reader to the following documents:

- WHO consolidated guidelines on tuberculosis. Module 5: Management of tuberculosis in children and adolescents. World Health Organization, Geneva, 2022.
- WHO operational handbook on tuberculosis. Module 5: Management of tuberculosis in children and adolescents. World Health Organization, Geneva, 2022.
- Union Deskguide for the Diagnosis and Management of Tuberculosis in Children.

3 Approach to CXR evaluation in children

CXRs remain the primary imaging tool for paediatric pulmonary TB, particularly in high TB-burden countries, where access to more advanced imaging is limited. It is important to have a systematic approach to CXR interpretation.

3.1 Basics of CXR interpretation

- Full-size CXRs must be taken.
- An antero-posterior (AP) or postero-anterior (PA) film must be available. AP films are taken from younger children who are unable or unwilling to stand independently, while the standard adult PA view is taken from older children who are able to cooperate.
- If possible, a lateral CXR should also be taken, especially in young children. The lateral film is helpful for seeing enlarged mediastinal lymph nodes and for localising lung pathology more accurately.
- All previous CXRs should be available for comparison to aid interpretation.
- Digital CXRs are preferable as the technical quality is better. Where analogue films are used it is important to use a good viewing box when interpreting. If you are comparing sequential CXRs, take care when comparing a digital film to an analogue film, as technical differences make comparison difficult.
- Always first check that you are interpreting the correct CXR from the correct patient (name and date).

3.2 Assessing technical quality

Once you have confirmed that you are looking at the correct CXR (check date) from the correct patient (check name) you should look at three aspects concerning the quality of the AP or PA CXR:

3.2.1 Rotation

The CXR is not rotated if:

- The two clavicle heads are the same distance from the midline (use the spinous processes of the vertebrae to identify the midline) and
- The anterior rib ends (more useful in children <5 years), which project over the lung fields, are the same distance from the lateral chest wall.

These aspects are easier to understand when visualised: see Figure 3.1.

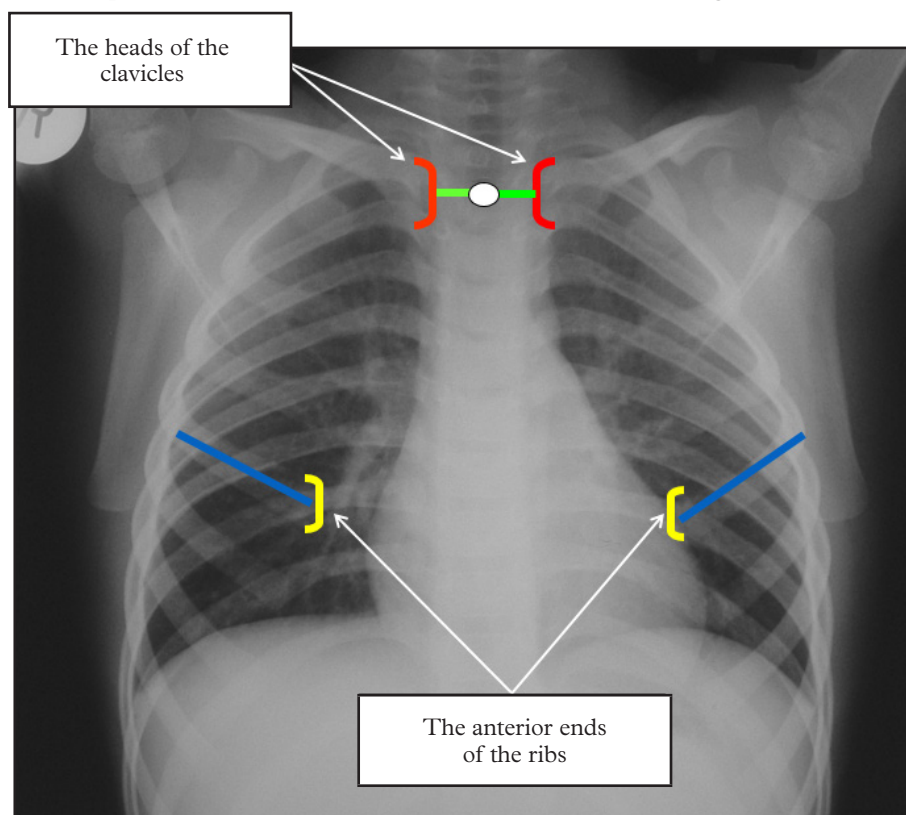


Figure 3.1: Note how the distance measured from the clavicle heads (marked in red) to the midline (green lines) on each side is the same; and the distance from the anterior rib ends (marked in yellow) to the lateral chest wall (blue lines) on each side is the same. Image courtesy of Professor Richard Pitcher.

3.2.2 Penetration

A CXR is correctly penetrated when:

- The intervertebral spaces can be distinguished through the heart shadow and
- The trachea and proximal bronchi are clearly visible.

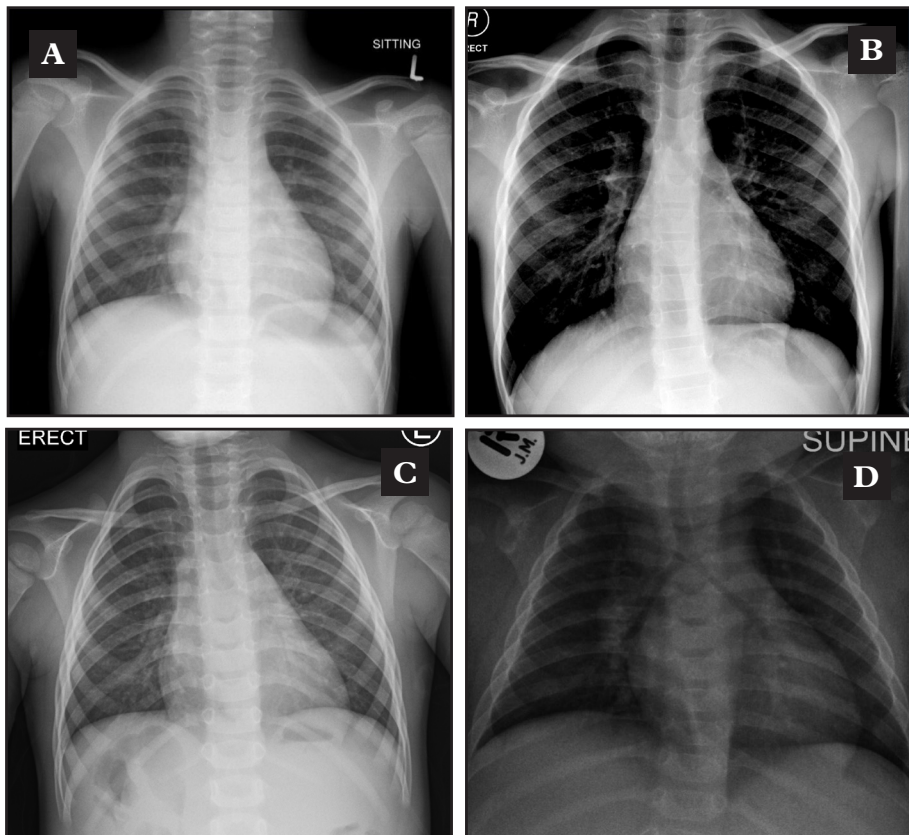


Figure 3.2: Compare CXR A to CXR B and CXR C to CXR D. CXR A and C are correctly penetrated films while CXR B and D are over-penetrated. When a CXR is over-penetrated the lungs appear blacker and pathology, such as opacification and lymph nodes may not be visible.

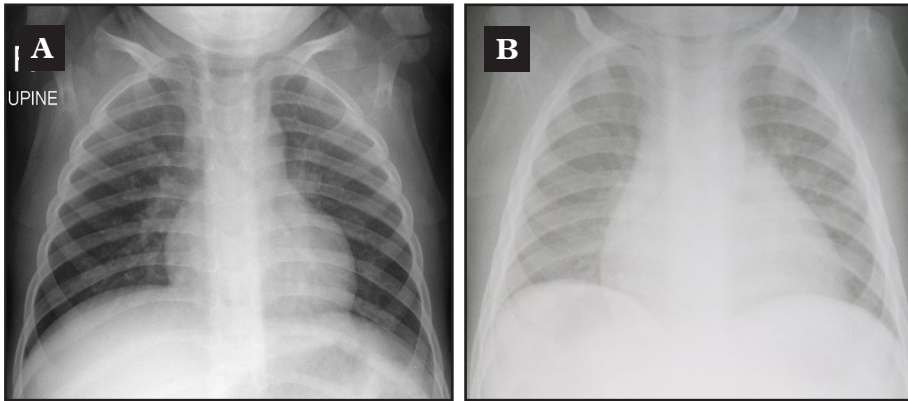


Figure 3.3: CXR A is a well-penetrated CXR while CXR B is under-penetrated. Note in CXR B the lungs appear whiter and you may over-interpret lung pathology. The airways are also not clearly seen on CXR B due to the under-penetrated.

3.2.3 Inspiration

Inspiration on the CXR is adequate when:

- The eight to ninth posterior rib is visible above the diaphragm (in young children you should always count posterior ribs) and
- The fifth whole anterior rib is visible above the diaphragm.

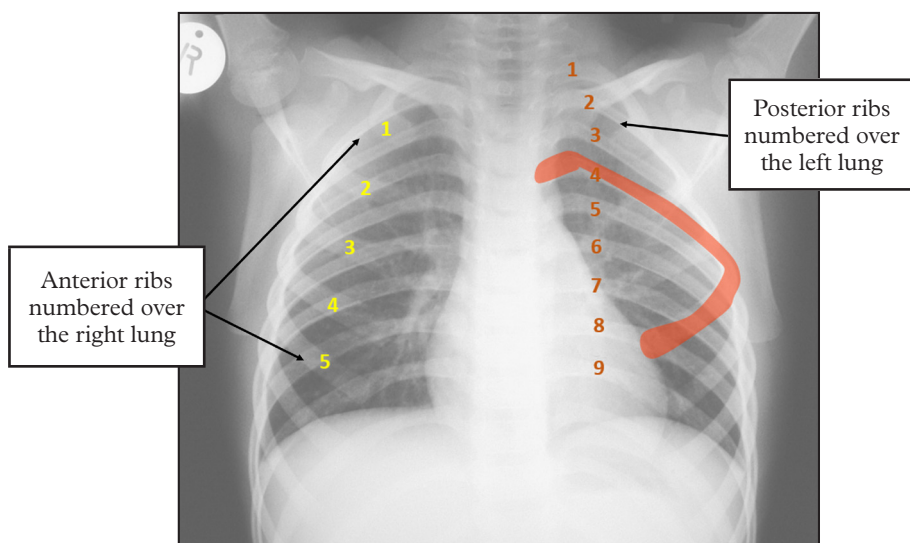


Figure 3.4: CXR annotated to demonstrate the counting of anterior and posterior ribs (anterior ribs are numbered over the right lung in yellow and posterior ribs are numbered over the left lung in orange) – this will allow the reader to assess adequacy of the inspiration. Image courtesy of Professor Richard Pitcher.

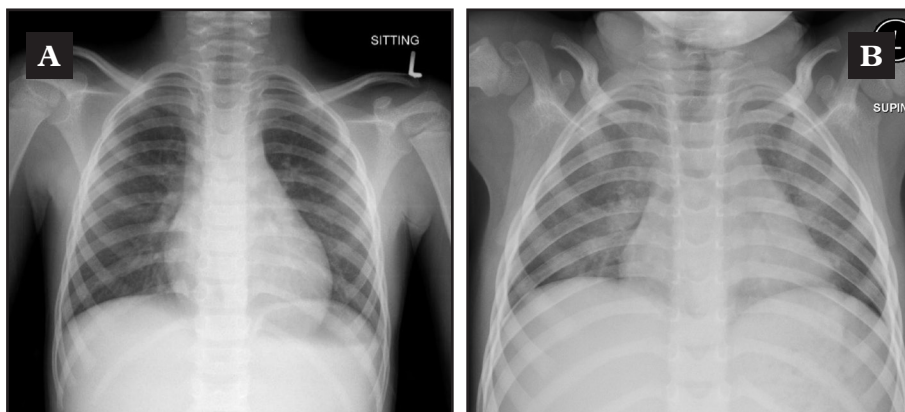


Figure 3.5: CXR A is a good inspiratory film: you can see five anterior ribs and nine posterior ribs above the diaphragm. CXR B is a poor inspiratory film – there are four anterior ribs and seven-eight posterior ribs. The heart looks large, the mediastinum appears wide, the lungs are under-penetrated (appear whiter), the airways are not well visualised and the hilar regions look full – this is all artefact due to poor inspiration and poor penetration. You can also see tracheal buckling on CXR B. This is when the trachea appears displaced (pushed) to the right on a poor inspiratory film.

3.3 Example of a systematic approach to paediatric CXR evaluation

After deciding that the technical quality of the CXR is acceptable, it should be examined in a systematic manner. There are several systematic approaches which are all acceptable and can be used – you should choose the one that makes the most sense to you and use it consistently. Below is an example of a systematic approach to CXR evaluation – see Figure 3.6 on page 21.

1. Look at the THREE structures that are white:

- 1.1. **Soft tissue and bone**

Examine the soft tissue of the chest for swelling, lumps or lymph nodes, the bony tissue for features, such as congenital abnormalities, periosteal reactions, fractures, signs of rickets or areas of infiltration or lucency (lytic lesions). TB can cause chest wall masses with rib involvement. Examine the spine for vertebral collapse or kyphosis (lateral CXR) and paraspinal abscess (AP/PA).

1.2. **Upper mediastinum**

Examine the upper mediastinum for position, size and shape and look specifically for a thymic shadow, any mediastinal masses and enlarged lymph nodes. The lateral CXR is useful for deciding whether a mediastinal opacity is in the anterior, middle or posterior mediastinum. This is important because knowing where the mediastinal opacity is can help to identify the structure.

1.3. **Heart shadow**

Examine the heart shadow for position, size and shape.

2. Look at the THREE structures that are black:

2.1. **Trachea and bronchi**

Follow the trachea and bronchi carefully looking for displacement or narrowing.

2.2. **Right and left lung**

When looking at the lungs always follow THREE steps:

- Compare the size of the two lungs.
- Compare the two lungs for areas of hyperlucency (this refers to areas of the lung that appear darker) and/or areas of opacity (this refers to areas of the lung that appear whiter).
- Compare the two hilar shadows for position, size and shape.

2.3. **Stomach bubble**

Look to ensure that the gas shadow in the stomach does not extend into the chest (this could indicate a diaphragmatic hernia). Also look for any other abnormalities below the diaphragms.

3. Check THREE aspects of the diaphragms and pleura:

3.1. **Position of the left and right diaphragms**

The diaphragms should be dome shaped (not flat) and the right diaphragm should be slightly higher than the left. Opacities (areas appear whiter) in the lung may blur the edge of the diaphragm.

3.2. **Two costophrenic angles**

The costophrenic angles, that is the angle where the diaphragm meets the thoracic wall, should be sharp on both sides. If they are blunt, then consider pleural pathology or effusion.

3.3. Pleura on both sides

Follow the outlines of the lungs on both sides – the normal pleura cannot be seen. Look for thickening of the pleura or fluid collections (these will appear white) in the pleural space. Section 5 gives examples of the appearance of pleural pathology on CXR.

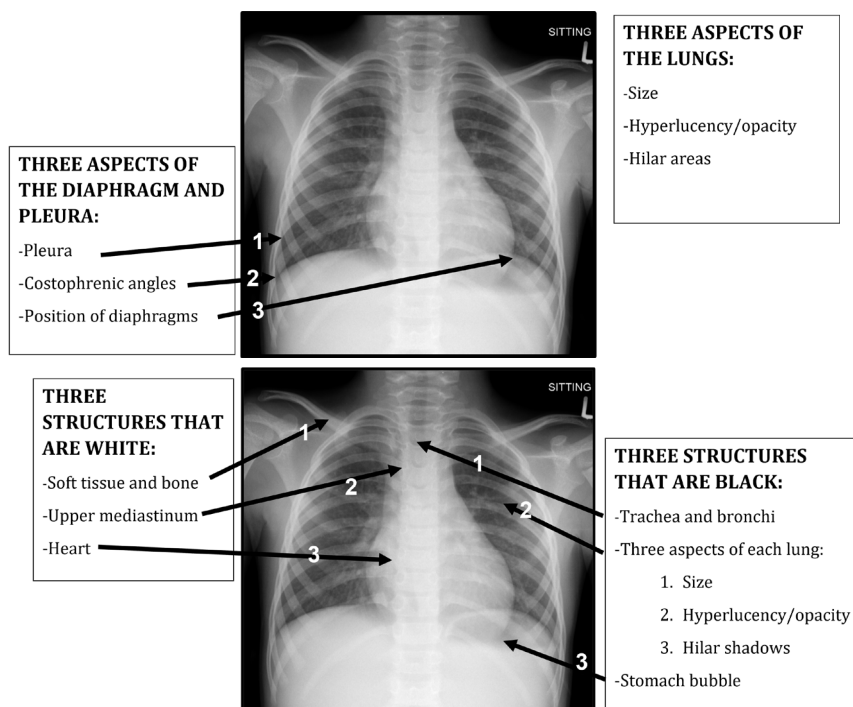


Figure 3.6: Systematic approach to CXR evaluation

3.4 Interpreting lateral CXR film

The lateral film is very helpful in paediatrics, especially in a child with presumptive pulmonary TB. Enlargement of the hilar lymph nodes may be visible on the lateral CXR when they are not visible on the AP/PA CXR. The lateral view also allows for better visualisation of the lung parenchyma that lies behind the heart and below the domes of the diaphragms. This can provide more certainty about the presence of pathology seen on the AP/PA film and help to better localise lesion - see Text Box 3.1.

Approach to interpretation of the lateral CXR - see Figure 3.7.

1. Identify the diaphragms
 - The right hemidiaphragm can be seen to stretch across the whole thorax and can be clearly seen passing through the heart border.
 - The left hemidiaphragm seems to disappear when it reaches the posterior border of the heart.
2. Compare the appearance of the lung fields in front of the heart and above the heart to those behind the heart
 - These areas should be of equal density if no other structures are present. Other structures that could be present are a large thymus anteriorly above the heart or opacities in the lung.
3. Look carefully at the area behind the sternum (called the retrosternal space)
 - This should be the blackest part of the film.
 - An anterior mediastinal mass will make this space look whiter/lighter.
4. Check position of the horizontal fissure
 - It should appear as a faint white line.
 - It should pass horizontally from the midpoint of the hilum to the anterior chest wall.

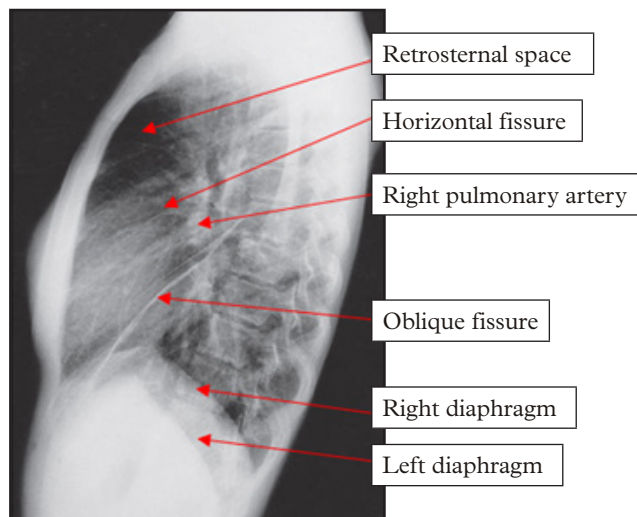


Figure 3.7: Anatomy of the lateral CXR film

Text Box 3.1: Using the lateral CXR film to localise lesions

Using the AP/PA and lateral films together will help you to localise lesions and identify where in the lung the abnormality is. Although knowing which lobe of the lung is involved is useful to understand, you can use CXRs to help you make clinical decisions without knowing this information.



3.5 Effect of age

When you are evaluating a CXR it is always important to know the age of the child. This is because both the normal anatomy and the radiological disease spectrum differs with age.

In younger children:

- It may be more difficult to get good quality images as they are less able to cooperate.
- The CXR is more likely to be AP than PA.
- The heart and mediastinum appear larger.
- The thymus may be visible and the upper mediastinum appears wider.
- The airways are more compressible which means that deviation or compression of the airways is more commonly seen.

Thymus

One of the normal structures that often causes considerable difficulty in deciding if the mediastinum is wider than usual is the thymic shadow. This is particularly relevant in paediatric TB because the thymic shadow may be mistaken for enlarged mediastinal lymph nodes. The thymus is normally not visible in children older than five years but should be considered in those under 5 years, and particularly in those under 2 years.

Characteristics of the thymus are:

- The classic shape on AP is triangular (the “sail sign”) but it can be of various shapes and sizes - see Figure 3.8 and Figure 3.10.
- Its shape may change with respiration and on repeat CXR.
- It is an upper mediastinal structure and:
 - It causes widening of the upper mediastinum on the AP.
 - It is seen as an opacity (increased whiteness) behind the sternum on the lateral film - see Figure 3.9.

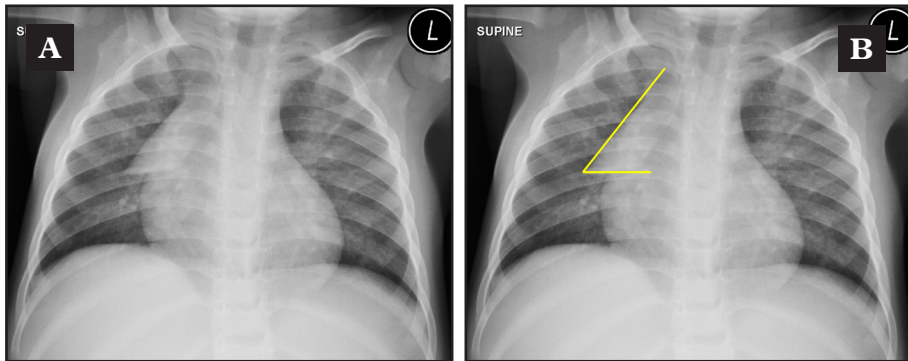


Figure 3.8: CXR B is an annotated version of CXR A, which is a CXR taken from a 1-year-old child. Note the triangular shape of the thymus on the AP film. This is the classic ‘sail sign’ appearance.

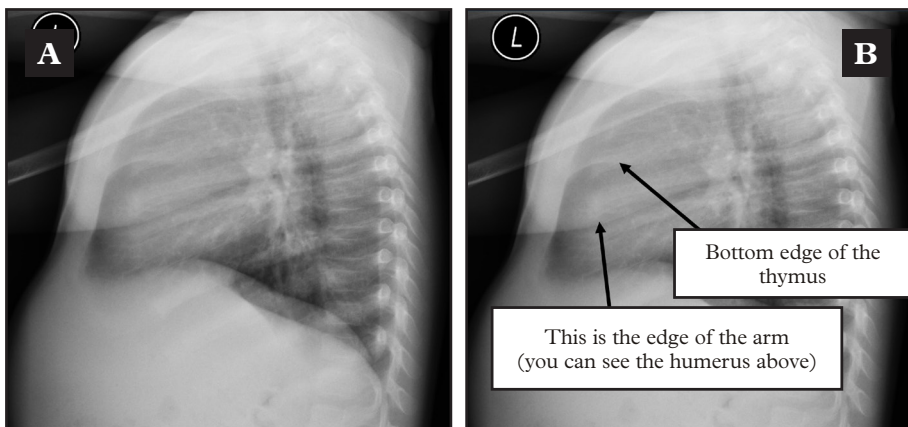


Figure 3.9: CXR B is an annotated version of CXR A, which is the lateral film which was taken from the same child at the same time as CXR in Figure 3.8. Note that the thymus appears as an opacity behind the sternum on the lateral film. Do not mistake the opacification (increased whiteness) of the arm with the thymus. For a good quality lateral CXR, the arms should be lifted up.

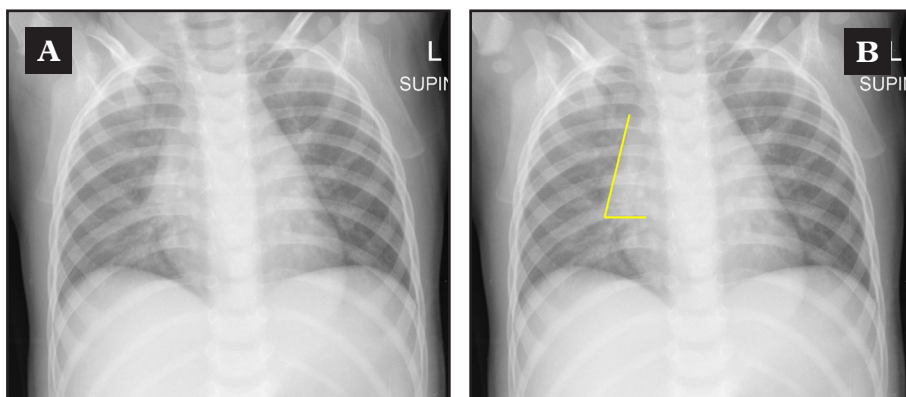


Figure 3.10: CXR B is an annotated version of CXR A. This CXR was taken from an 8-month-old infant. This is another normal AP CXR showing the triangular shaped thymus.

3.6 Effect of HIV infection

The impact of HIV infection is important to discuss. HIV infection increases the risk of progression to TB disease following infection and increases the risk of severe, disseminated types of TB. In addition, children living with HIV are at high risk of other infectious diseases and other lung conditions that can present in a similar way to TB. Children living with HIV frequently have had multiple previous chest infections and often have some degree of residual lung scarring and damage leading to chronic symptoms and CXR changes that could be confused with TB. These factors result in symptoms and signs of TB being less sensitive and specific for TB in children living with HIV and many of the investigations used to evaluate a child for TB (including CXR) are less useful. The use of antiretroviral therapy (ART) substantially reduces these risks and in children who were diagnosed with HIV early and who have consistently taken their ART since a young age, the risk for TB disease is fairly similar and the CXR features of TB on CXR are similar to those in children without HIV.

3.7 Sensitivity and specificity of different CXR features for paediatric TB

In this Atlas we use the approach of classifying CXR features as being more or less specific to TB. This approach was chosen because the features of TB on CXR in children are variable: ‘the CXR can look like anything’. Despite this, some CXR features make a diagnosis of TB disease much more likely than other CXR features – these (more specific) features will probably help your diagnostic decision-making more than the other (less specific) features will. For example, enlarged mediastinal lymph nodes are commonly seen in children with pulmonary TB and are seldom seen in other diseases – if you are working in a high TB-burden setting and you see enlarged mediastinal lymph nodes on CXR in a symptomatic child you can confidently diagnose pulmonary TB.

Text Box 3.2 explains the concepts of sensitivity and specificity in more detail. The CXR patterns described in Section 5 are all classified according to their specificity for TB.

Text Box 3.2: Understanding sensitivity and specificity

If a test has high sensitivity for a disease then, when it is negative, you can confidently say that the person does not have the disease (there are few false negatives). When the test is positive, however, you cannot confidently say that the person has the disease (the possibility for false positives is high).

A negative test that has high **SeNsitivity**
rules the disease **OUT**

SNOUT

If a test has high specificity for a disease then, when it is positive, you can confidently say that the person does have the disease (there are few false positives). When the test is negative, however, you cannot confidently say that the person does not have the disease (the possibility for false negatives is high).

A positive test that has high
SPecificity rules the disease **IN**

SPIN

Screening tests are typically more sensitive as they aim to identify everyone who MIGHT have the disease without missing anyone. If a person has a positive screening test this is usually followed with a diagnostic test.

Diagnostic tests are typically more specific as they aim to not mis-classify anyone as having disease (and receiving treatment) when they do not.

This Atlas aims to assist in the diagnosis of pulmonary TB, and CXR features are classified as being either 'specific' or 'less specific' for pulmonary TB. If you see a child with presumptive pulmonary TB with one of the CXR features with high specificity (>90%) for pulmonary TB you can very confidently diagnose that child with TB and start treatment.

The absence of these specific CXR features does not rule out pulmonary TB but should encourage the healthcare worker to look for other evidence to support or exclude the diagnosis. In these cases the CXR may not have been that helpful in the decision-making process.

4 Algorithmic approach to CXR evaluation in a child with presumptive pulmonary TB

When evaluating a CXR from a child with presumptive pulmonary TB you should use the systematic approach to CXR interpretation described above and the information that follows in Section 5 to answer the following questions - see Figure 4.1:

1. Is the technical quality of the CXR acceptable?
2. Is the CXR normal or abnormal?
3. If abnormal, are there radiological features which have high specificity for pulmonary TB?
If yes, then you can confidently diagnose pulmonary TB and start treatment. Remember to always collect samples (respiratory, stool or urine) before starting treatment.
4. If abnormal, are there radiological features of severe disease?
If non-severe disease, then consider using a shorter treatment regimen - see Section 6.




Figure 4.1: Algorithm for CXR interpretation in a child with presumptive pulmonary TB

Remember that the CXR should not be interpreted in isolation and this algorithm for CXR interpretation should be used together with a comprehensive diagnostic algorithm for paediatric TB.

Note on Computer-Aided Detection of TB on CXR

In 2021, the World Health Organization (WHO) recommended that ‘among individuals aged 15 years and older in populations in which TB screening is recommended, computer-aided detection (CAD) software programmes may be used in place of human readers for interpreting digital CXRs for screening and triage for TB disease’. At the start of 2022, CAD software programmes had not yet been optimised or validated for paediatric populations and this recommendation did not extend to children. However in the future, CAD of TB on CXR may become a useful tool for the diagnosis of paediatric TB.

5 The specific and less specific CXR features for paediatric TB

This Section describes the CXR patterns seen in children with pulmonary TB and will help you to decide if a CXR is normal or abnormal and whether there are features that have high specificity for pulmonary TB or not. Understanding what a normal CXR looks like is important and the more CXRs you look at, the easier it will become.

Remember that the guidance in this Atlas is applicable to the clinical evaluation of a symptomatic child with presumptive TB living in a low-resource, high TB-burden setting.

In the context of paediatric TB it is important to keep the following in mind:

- TB in children is not a static disease and disease progression correlates with evolving CXR features. Consequently, findings on CXR range from the absence of radiological abnormality (normal CXR) through non-severe, uncomplicated disease to extensive, complicated pulmonary disease.
- The spectrum of disease seen on CXR is influenced by the age of the child, the child's HIV status and the presence of other co-morbidities.
- CXR features with high specificity for TB are very useful in diagnostic decision-making: if a child with presumptive pulmonary TB has any of these specific CXR features, you can confidently diagnose TB and you should start TB treatment. Do not forget to collect respiratory, stool or urine samples for TB tests if you can. However, many children treated for pulmonary TB in routine care may have normal or non-specific CXR features. This is particularly true of children with early, non-severe disease and those found through contact tracing with early symptoms. In these cases the CXRs may be less helpful in diagnostic decision-making. While a normal CXR does not conclusively rule out TB, it is generally reassuring and reduces the probability that the child has (pulmonary) TB disease. If the CXR is not normal but shows less specific features of pulmonary TB, then the CXR has been less helpful in your diagnostic decision-making process and there is a greater reliance on the clinical presentation and results of other tests.

- Remember the value of repeating the CXR. When the clinical picture and CXR features are unclear and have not helped you to make a diagnosis, then careful clinical follow-up and repeat imaging in 2 weeks can be very helpful.
- If you have decided that the child has TB and you plan to start TB treatment, then the next step is to use the CXR to decide whether to treat for severe or non-severe disease. This is discussed in Section 6. Remember that the assessment of disease severity includes an assessment of the clinical and microbiological information in addition to an assessment of the CXR.

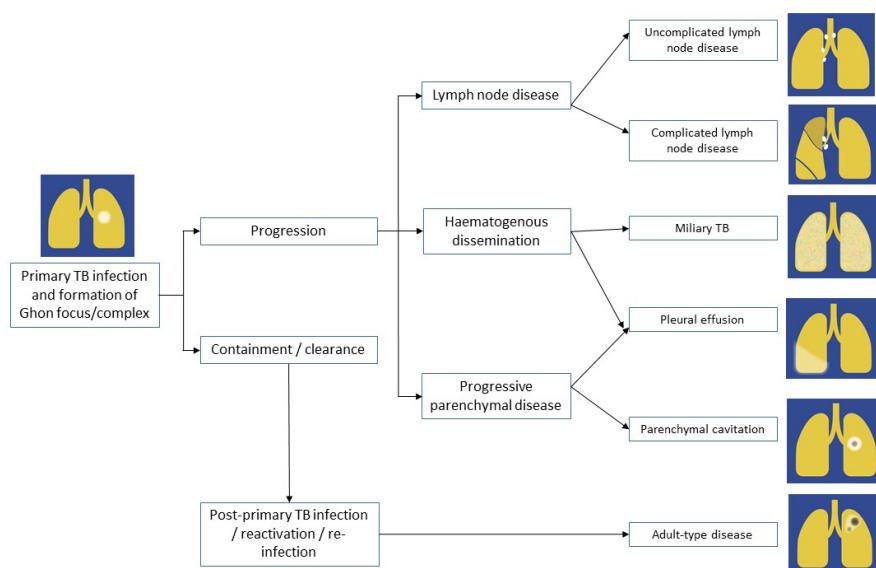



Figure 5.1: Well-recognised typical CXR features for paediatric pulmonary TB that have high specificity for pulmonary TB

5.1 Normal CXR



- In a symptomatic child with presumptive pulmonary TB and a normal CXR a careful clinical assessment should be undertaken to exclude alternative diagnoses. However, a normal CXR does not exclude the diagnosis of TB. If possible, respiratory and other specimens should be collected and sent for TB tests. Depending on the age of the child and clinical context, you may decide to start TB treatment even though the CXR is normal, or you may decide to repeat the clinical assessment (including an assessment for extra-pulmonary TB disease manifestations) and CXR with/without a course of antibiotics. Serial imaging is useful in these children. If you decide not to treat for TB disease but the child is TB exposed, then do not forget to start TPT.
- Note that the normal CXR looks different in children of different age groups - see Section 3.5 It is always important to know the age of the child before interpreting the CXR - see Figures 5.2-5.4.

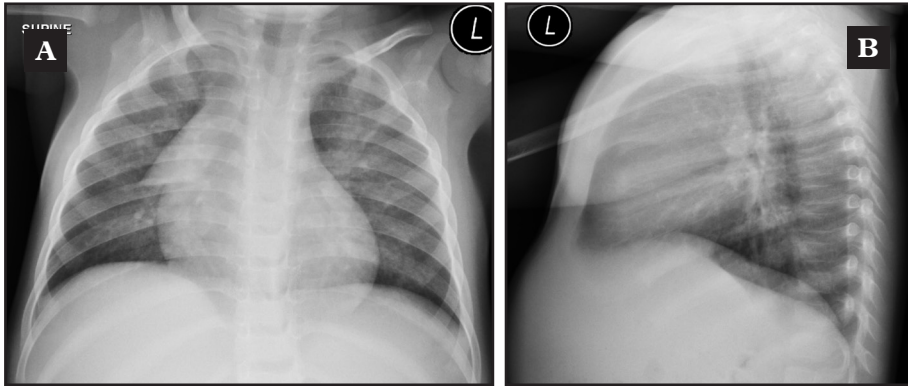


Figure 5.2: CXR A and B are normal AP and lateral CXRs from a 1-year-old infant - note the relatively wide mediastinum, large cardiac shadow and triangular thymic shadow on CXR A (this CXR is a bit rotated).

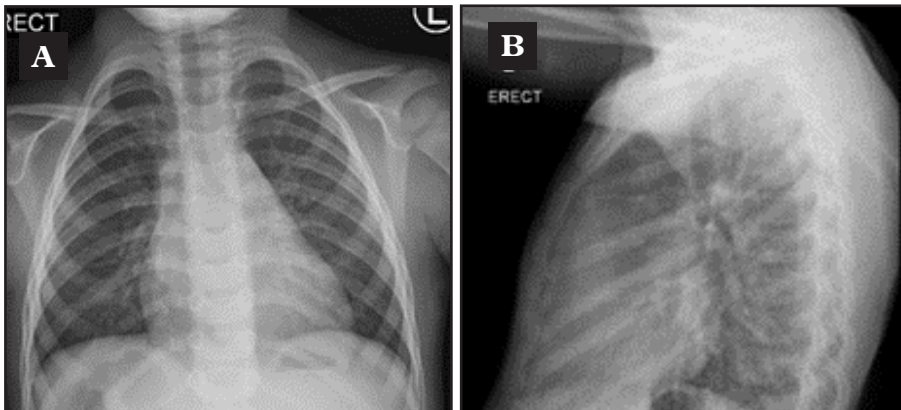


Figure 5.3: CXR A and B are normal AP and lateral CXRs from a 6-year-old child - note there is no thymus visible, the mediastinum is narrower and the cardiac shadow is not as big as in younger children.

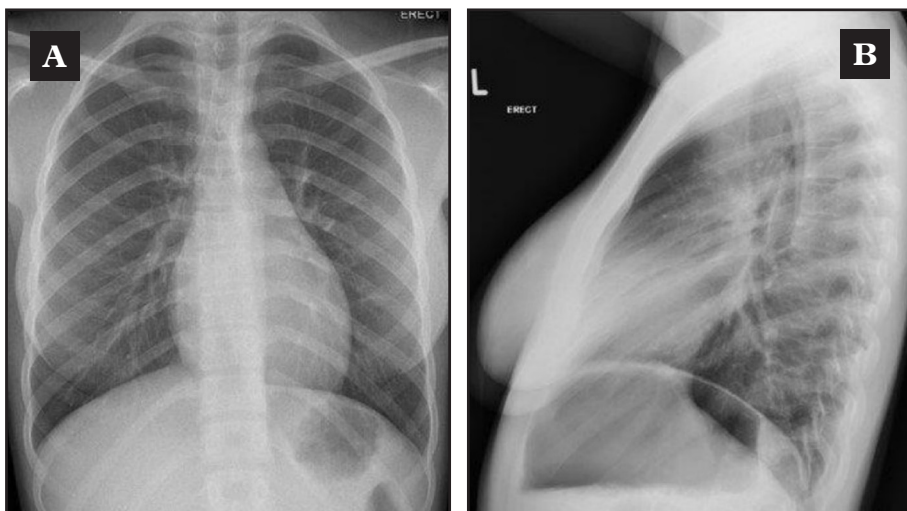



Figure 5.4: CXR A and B are normal PA and lateral CXRs from a 12-year-old girl – the anatomy is similar to that of an adult with a narrow upper mediastinum, cardiothoracic ratio of $<50\%$ and visible breast tissue.

5.2 CXR features which are very specific to paediatric TB

Remember that CXR features that have high specificity for pulmonary TB are very seldom seen in children without pulmonary TB – this means that they are very helpful in your diagnostic decision-making (a positive result from a very **SP**ecific test helps to rule the disease **IN** – **SPIN**). If you see one of these features in a child with presumptive TB you should start TB treatment. Wherever possible, specimens should first be collected and sent for TB tests.

There are some CXR features that have high specificity for pulmonary TB and strongly support the diagnosis of pulmonary TB, but the absence of these features does not exclude the diagnosis.



5.2.1 Primary (Ghon) focus and complex

Pathogenesis of the primary (Ghon) complex

After inhalation, the TB bacilli settle in the alveoli where single or multiple foci proliferate to form the primary focus (or Ghon focus). The bacilli can then spread from the parenchymal primary focus, via the lymphatic system, to the nearest mediastinal lymph nodes.

Consequently, three CXR patterns can develop:

1. A primary focus in isolation - this is very rarely seen on CXR or
2. Enlarged mediastinal lymph nodes in the absence of a visible primary focus - this is commonly seen on CXR or
3. A primary focus together with enlarged mediastinal lymph nodes - this is called a primary complex or Ghon complex and is uncommonly seen on CXR.




In many cases, the bacilli are contained at this stage and the child does not develop disease. However, there is usually an immune response which causes a positive TST or IGRA.

The primary (Ghon) focus

The primary focus in isolation is an uncommon CXR feature. It can occur in any of the lobes of the lung as particle deposition is determined by the distribution of ventilation. It tends to occur 1-2 cm from the pleura, is normally poorly circumscribed and is less than 1 cm in diameter. A child can also have more than one primary focus and an overlying pleural reaction may be visible on CXR.

The primary (Ghon) complex

The primary complex is made up of the primary focus and mediastinal lymph node enlargement. However, **it is more common to see enlargement of the mediastinal lymph nodes without seeing the primary focus** - see Section 5.2.2. Sometimes the primary complex is seen as a calcified (older, inactive) nodule in the lung with enlarged lymph nodes in the mediastinum - see Figure 5.5.

The primary (Ghon) focus 		Very uncommon
		Very specific
	<div>NON-SEVERE</div>	Non-severe

**A primary focus (without associated lymphadenopathy)
is very rarely seen on CXR.**

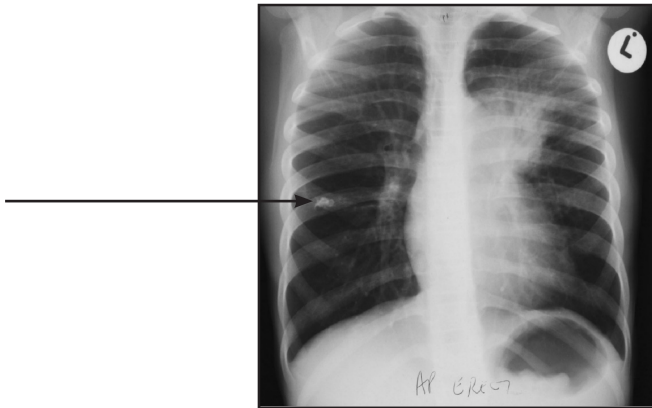


Figure 5.5: Note the presence a calcified primary (Ghon) focus (see arrow) and left hilar lymph node enlargement. There is infiltration of the lung parenchyma in the left upper lobe.

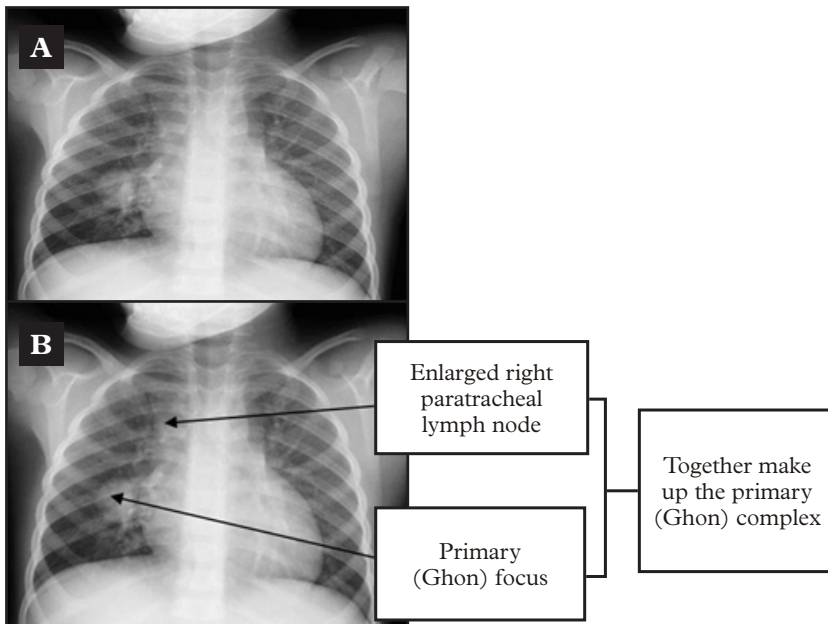


Figure 5.6: CXR B is an annotated version of CXR A. This CXR shows a primary (Ghon) complex

5.2.2 Lymph node disease

Mediastinal lymph node enlargement is the hallmark feature of paediatric pulmonary TB and is a consequence of the TB bacilli seeding to the lymph nodes from the lung parenchymal focus via the lymphatics. Together, paratracheal and hilar (which includes sub-carinal) lymph nodes are referred to as mediastinal lymph nodes.

If there are enlarged paratracheal lymph nodes in the absence of associated perihilar or sub-carinal lymph node enlargement, care should be taken not to miss the differential diagnosis of lymphoma. Enlargement of mediastinal lymph nodes is more commonly seen in younger children (<5 years) with pulmonary TB and less commonly seen with increasing age.

Enlargement of the mediastinal lymph nodes on CXR can be uncomplicated or complicated.

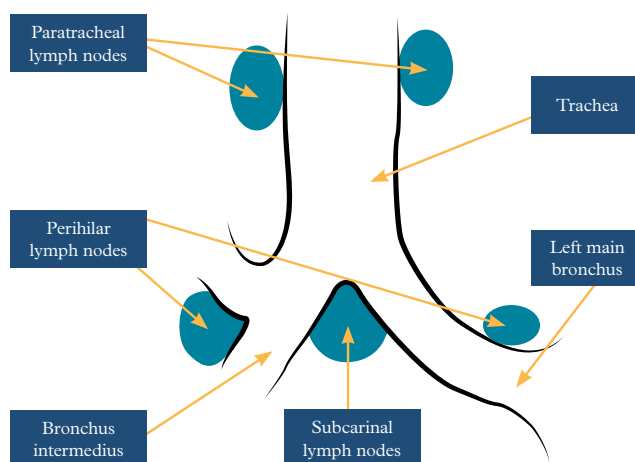


Figure 5.7: Anatomical position of mediastinal lymph nodes

Useful points about enlarged perihilar lymph nodes on AP/PA CXRs:

1. They look like lobulated radio-opaque (white/lighter) structures in the hilar areas.
2. They can cause the shape of the hilum to be convex (bulging) outwards. The usual shape of the hilum is concave (curved inwards). This is more easily understood by looking at Figures 5.8 to 5.9.

3. They may be more easily seen on the lateral film.
4. They include sub-carinal lymph nodes. Enlargement of sub-carinal lymph nodes, although not always visible on CXR, are present in most children with pulmonary TB. They are seen as an enlargement or fullness in the space below the carina.

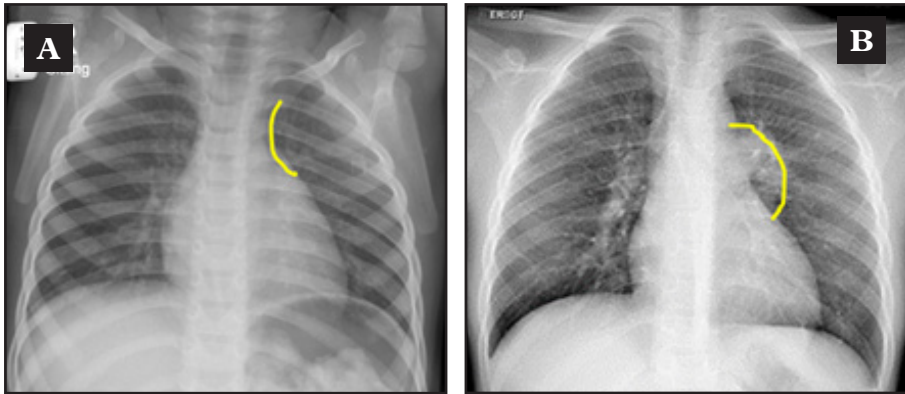


Figure 5.8: CXR A is normal - note how the hilar region has an inward convex shape. CXR B is abnormal and shows an enlarged left perihilar lymph node - note how the shape of the hilar region curves inwards.

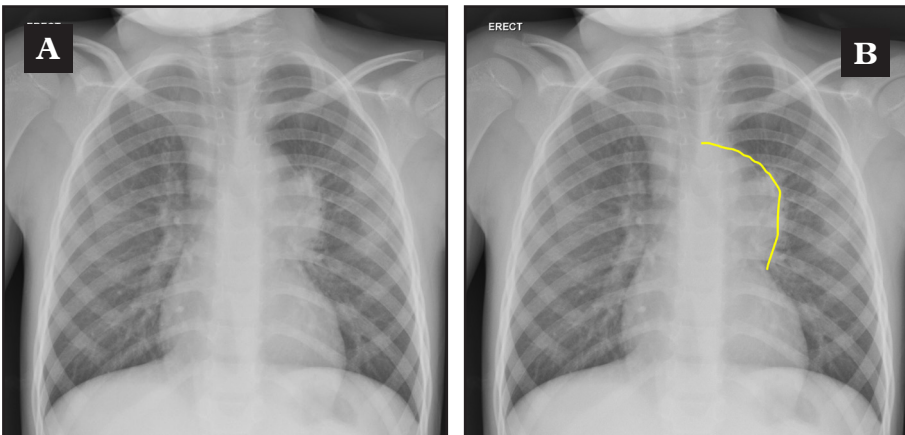


Figure 5.9: Another example of an enlarged left perihilar lymph node - CXR B is an annotated version of CXR A and shows the typical outline of an enlarged perihilar lymph node.

Useful points about enlarged paratracheal lymph nodes on AP/PA CXRs:

- They cause widening of the upper mediastinum.
- They bulge outwards changing the contour of the upper mediastinum - see Figures 5.10-5.12.
- Interpretation of an upper mediastinal mass can be complicated in the presence of the thymus in infants or young children (especially <2 years).

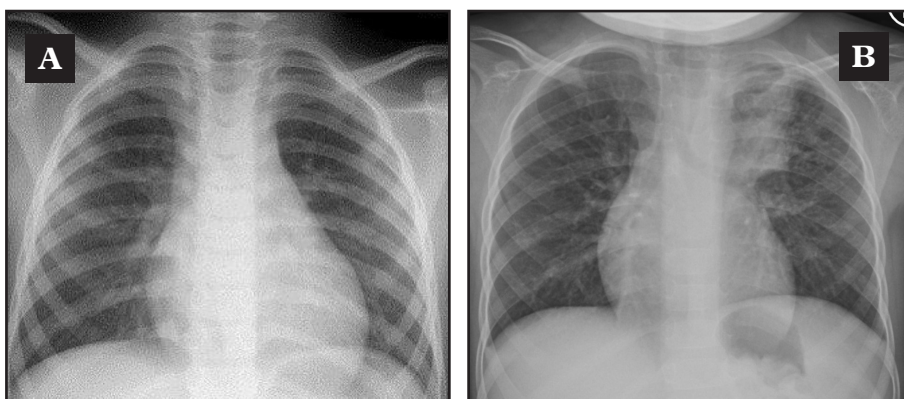

Figure 5.10: CXR A is normal, while CXR B shows the characteristic shape of an enlarged paratracheal lymph node - note the widening of the upper mediastinum on the left and the radio-opaque structure bulging outwards.

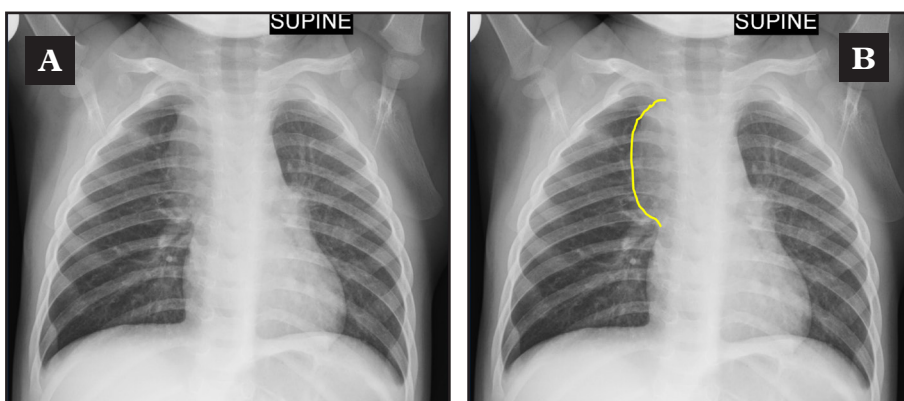


Figure 5.11: Another example of an enlarged paratracheal lymph node – this time on the right. CXR B is an annotated version of CXR A.

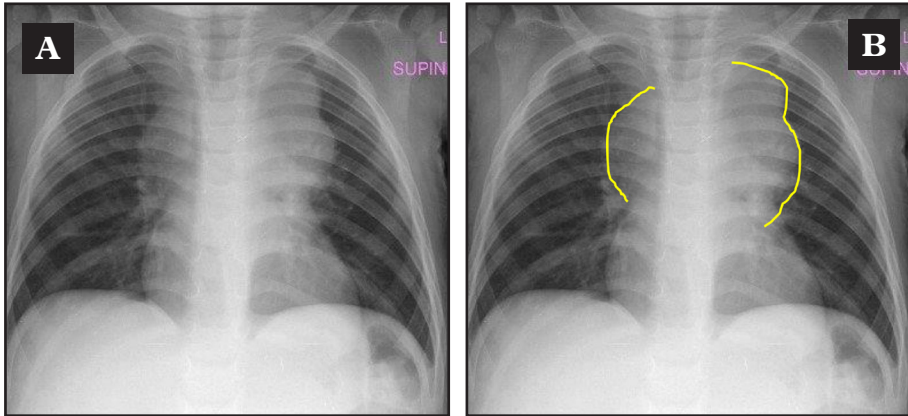


Figure 5.12: CXR B is an annotated version of CXR A - note that the mediastinum is wide and there are bilateral lobulated opacities in the mediastinum – these are enlarged paratracheal and hilar lymph nodes.

Using the lateral CXR to identify enlarged mediastinal lymph nodes:

- Enlarged perihilar lymph nodes can sometimes be seen on the lateral film when they are not clearly seen on the AP/PA film.
- Enlarged perihilar lymph nodes appear as rounded opacities at the lower end of the trachea - see Figures 5.13 which illustrates the “doughnut” or “hamburger” sign.
- Enlarged paratracheal lymph nodes fill the middle mediastinum whereas the thymus fills the anterior mediastinum - see Sections 3.4 and 3.5.

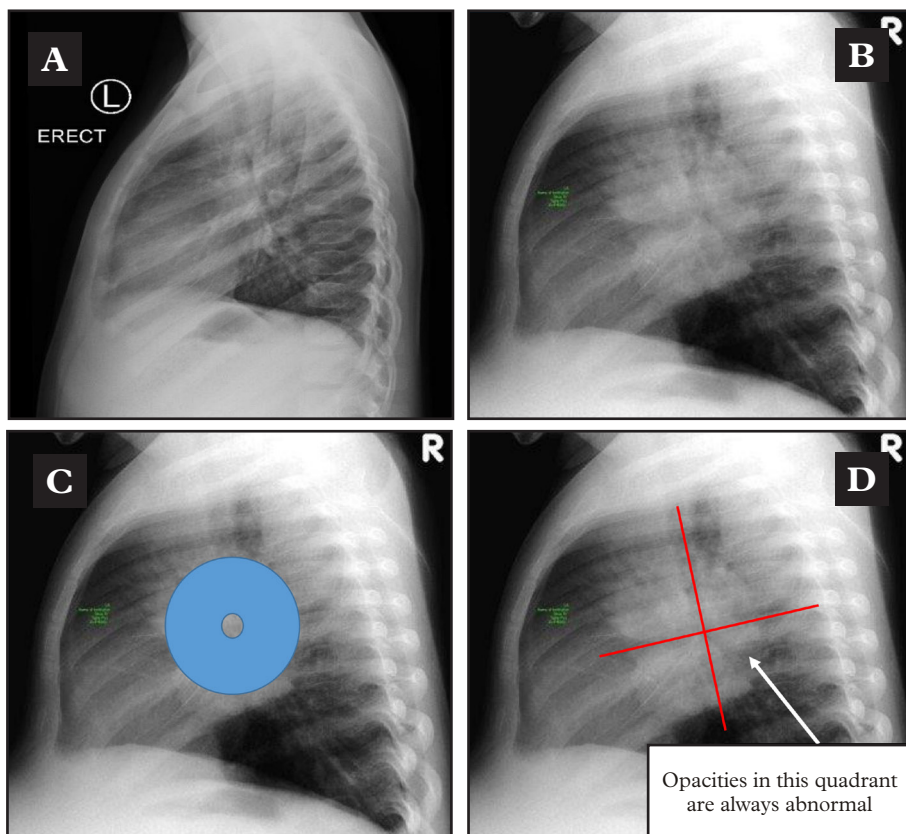


Figure 5.13: CXR A is a normal lateral film while CXR B is an abnormal lateral film with enlargement of the perihilar lymph nodes. CXRs C and D are annotated versions of CXR B. CXR C shows the “doughnut” or “hamburger” sign - the enlarged lymph nodes, posteriorly and inferiorly, make up the bottom half of the doughnut and the normal vascular structures make up the top half. CXR D demonstrates another useful trick that can be used to identify enlarged lymph nodes on the lateral CXR - draw a straight line downwards following the trachea and then draw a line perpendicular to this where the trachea ends (bifurcates) so that you have made a cross with 4 quadrants. Opacities in 3 of these 4 quadrants may represent normal anatomy but an opacity in the inferior posterior quadrant is always abnormal and likely represents enlarged sub-carinal lymph nodes.

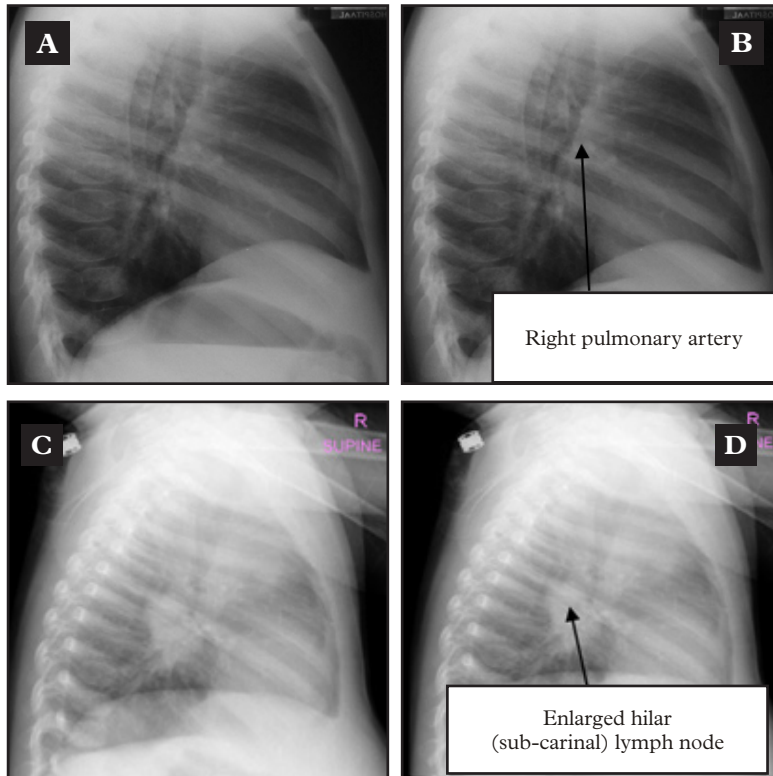
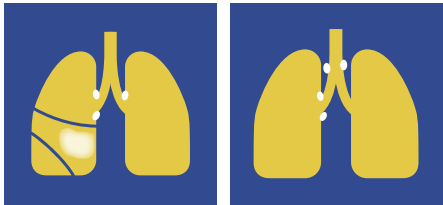





Figure 5.14: CXR B is an annotated version of CXR A. This is a normal lateral film - note the the opacity in front of the trachea which is the normal right pulmonary artery. CXR D is an annotated version of CXR C and shows an opacity that is located inferiorly and posteriorly – this is abnormal and represents an enlarged hilar (sub-carinal) lymph node. These lateral films are the other way around to the ones above so the inferior posterior quadrant is on the other side - don't be confused!

The following Sections describe and illustrate the differences between Uncomplicated and Complicated lymph node disease on CXR. It is important to know the difference because Uncomplicated lymph node disease is a non-severe radiological pattern while Complicated lymph node disease is severe. This may impact on the treatment regimen you choose.

Enlargement of mediastinal lymph nodes is the radiological hallmark of paediatric pulmonary TB.

Uncomplicated lymph node disease

Uncomplicated lymph node disease 		Very common
		Very specific
		Non-severe

Uncomplicated lymph node disease refers to the presence of enlarged mediastinal lymph nodes with:

1. NO significant airway compression AND
2. Either minimal (<1 lobe) or no parenchymal involvement.

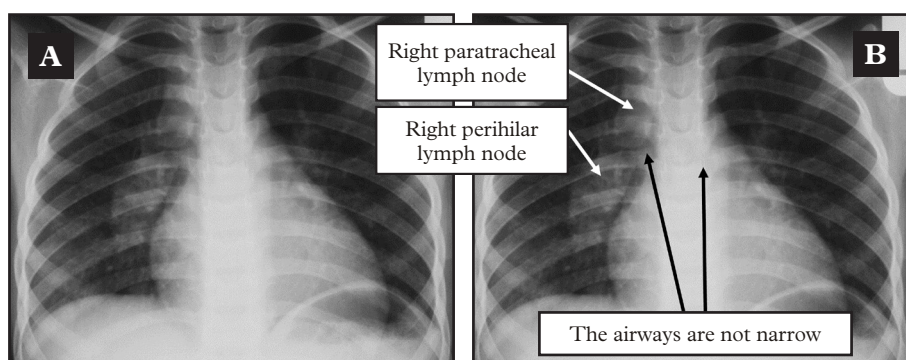


Figure 5.15: CXR B is an annotated version of CXR A which was taken from a 3-year-old child. This CXR shows an enlarged paratracheal and perihilar lymph nodes on the right, with no airway or parenchymal involvement. This is radiologically non-severe disease.

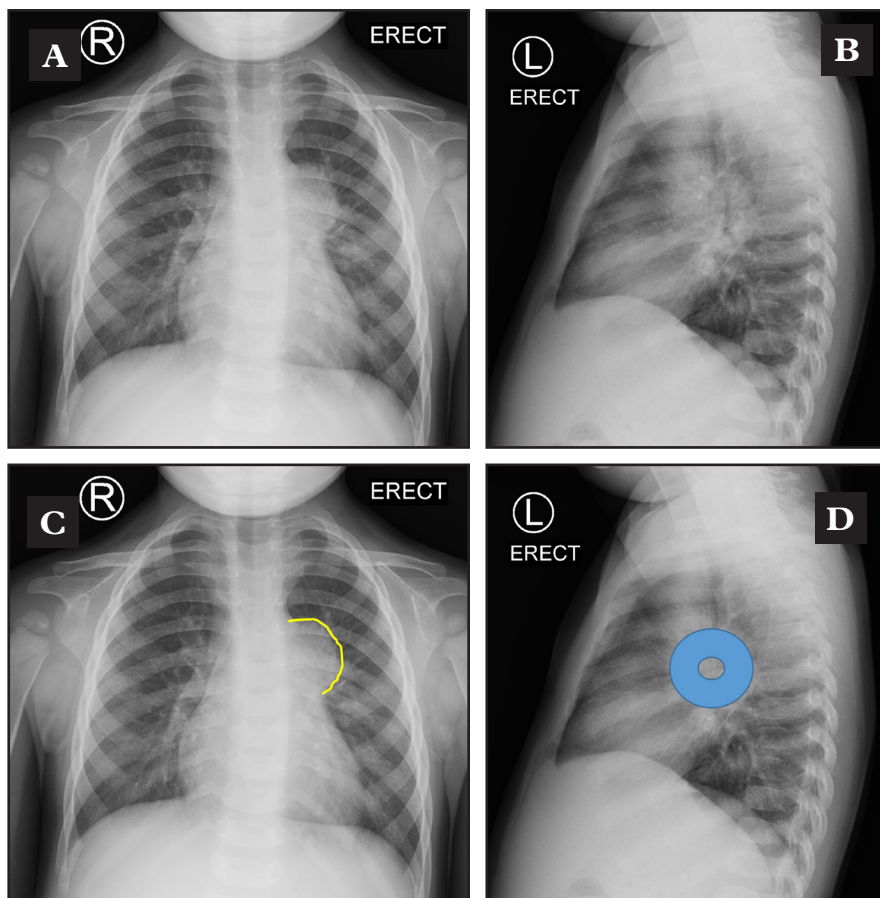


Figure 5.16: CXR C and D are annotated versions of CXR A and B. These are AP and lateral films taken from a 4-year-old child. They show enlargement of left perihilar lymph nodes with no airway or parenchymal involvement. Note the annotated doughnut/hamburger sign on CXR D. This is radiologically non-severe disease.

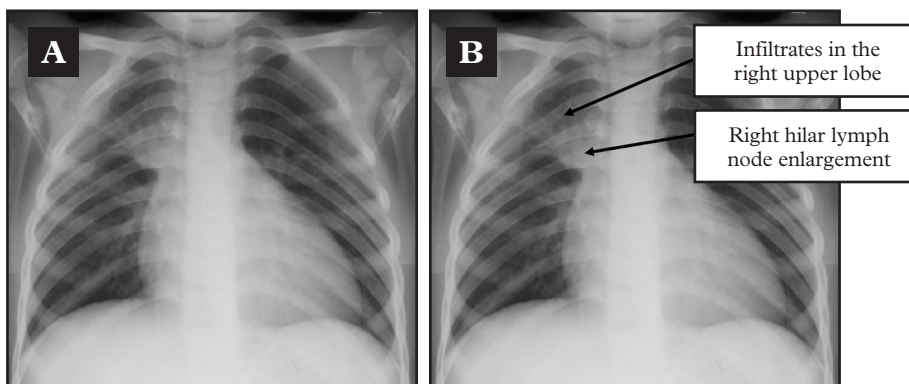


Figure 5.17: CXR B is an annotated version of CXR A taken from a 4-year-old child. This CXR shows hilar lymph node enlargement with segmental (<1 lobe) parenchymal involvement. This is radiologically non-severe disease.

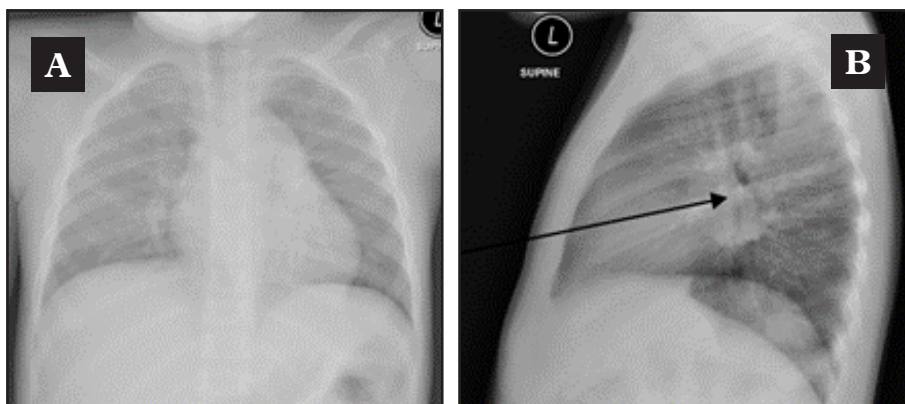


Figure 5.18: CXR A and B are a set of AP and lateral CXRs taken from a 3-year-old child. CXR A is poor quality - slightly rotated, poorly inspired and under-penetrated. In such cases the lateral film, CXR B, is very helpful. The arrow shows the enlarged hilar lymph nodes which are clearly seen on the lateral film.

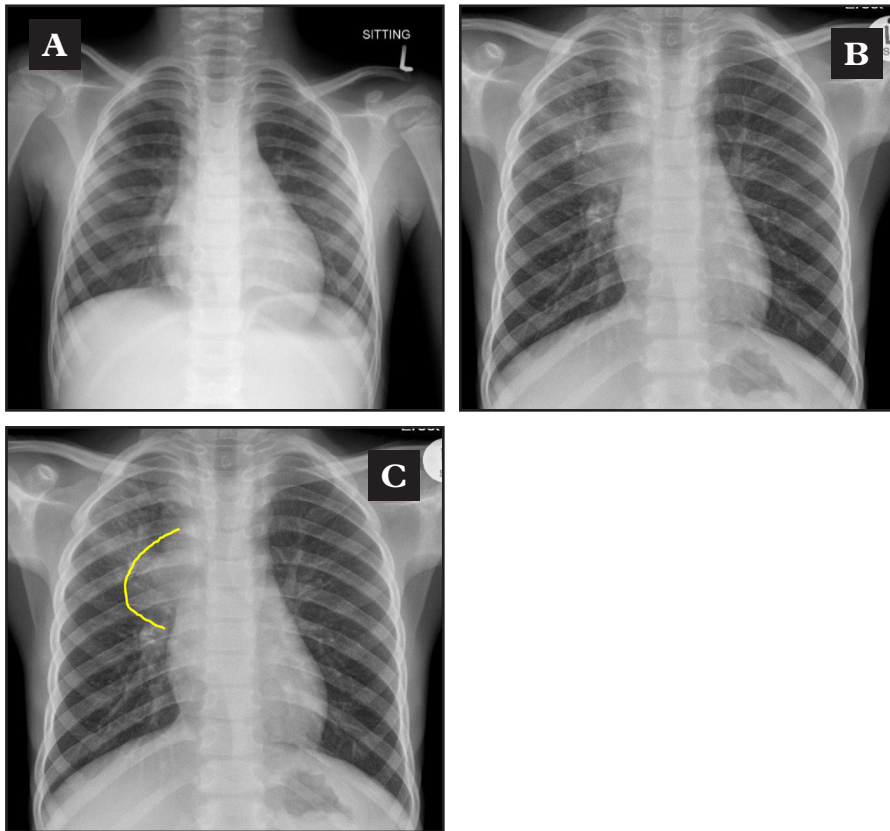


Figure 5.19: These CXRs are from 5-year-old children. CXR A is a normal CXR - note the normal concave shape of the right hilum. CXRs B and C are the same CXR but CXR C is annotated to show the opacity in the right hilar region that bulges outwards - this is not normal and is an enlarged right perihilar lymph node. This is radiologically non-severe disease.

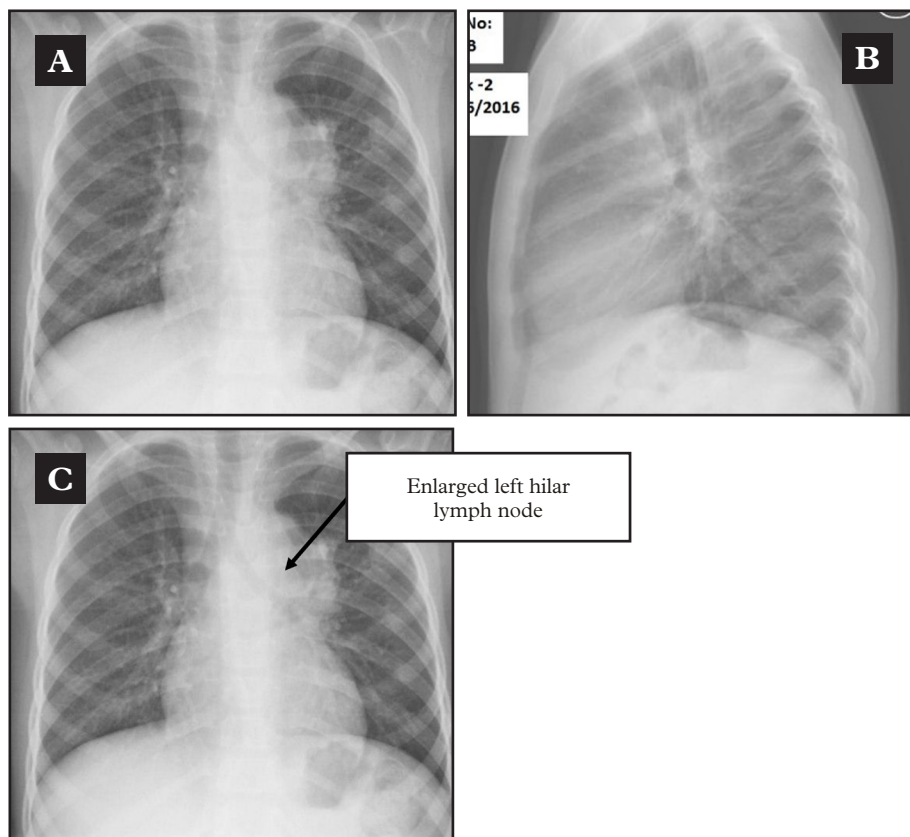


Figure 5.20: CXR A and B are a set of CXRs from a 5-year-old child. CXR C is an annotated version of CXR A. The enlarged left hilar lymph node is clearly seen on the AP films (CXR A and CXR C), but is less clear on the lateral (CXR B). The airways are patent (not narrowed or deviated from their normal position). There is no involvement of the lung parenchyma. This is radiologically non-severe disease.

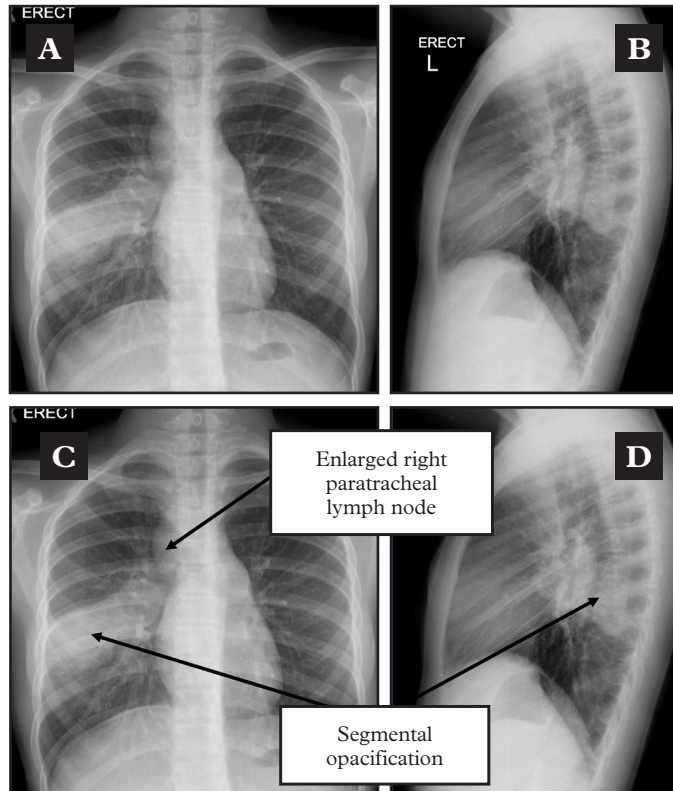


Figure 5.21: CXRs A and B are a set of AP and lateral CXRs taken from a 4-year-old child. CXRs C and D are the same set of CXRs but these are annotated. These CXRs show segmental opacification of the right lower lobe with right-sided paratracheal lymph nodes. This is radiologically non-severe disease. See Text Box 3.1. to review how to localise lesions in the lungs.

Complicated lymph node disease

Complicated lymph node disease includes the presence of enlarged mediastinal lymph nodes AND:

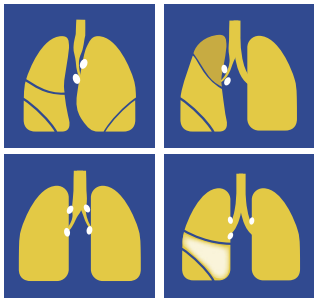



1. Airway compression or deviation AND/OR
2. Associated hyperinflation/collapse AND/OR
3. Extensive (≥ 1 lobe) parenchymal involvement.

Lymph node TB that involves the airways may be referred to as lymphobronchial TB.

Sometimes the enlarged lymph nodes cannot be seen but the consequences of them can be seen as abnormalities of the large airways:

- Compression and/or deviation of the bronchi.
- Deviation of the trachea (compression possible but less common).

Airway involvement is more commonly seen in younger children because they have more compressible airways.

Complicated lymph node disease 		Uncommon
		Very specific
		Severe

Large airway compression

Enlarged lymph nodes can cause compression or deviation of the large airways (trachea and bronchi). Airway compression is more common in children <2 years of age. Enlarged lymph nodes alongside the trachea can cause the trachea to be deviated from its normal position and away from the enlarged lymph node (the calibre of the airway may be normal with no visible narrowing on CXR). Enlarged lymph nodes alongside the bronchi can cause either compression or deviation of the bronchi. Compression is caused when the airway is squashed between two groups of lymph nodes and the airway looks narrower than normal. Deviation is where the airway is not narrow but has been pushed away from its normal position. **To interpret airway compression or deviation the CXR must be taken in good inspiration.**

The potential consequences of large airway compression are unilateral hyper-inflation and/or lobar/segmental collapse. These are described below. Children with large airway compression may present with a monophonic wheeze. A monophonic wheeze is a wheeze that has one frequency or pitch whereas a polyphonic wheeze, heard in bronchiolitis or other small airway diseases, changes frequency or pitch as you listen.

In young children, compression or deviation of the large airways can indicate enlargement of mediastinal lymph nodes, even if the lymph nodes cannot be seen.

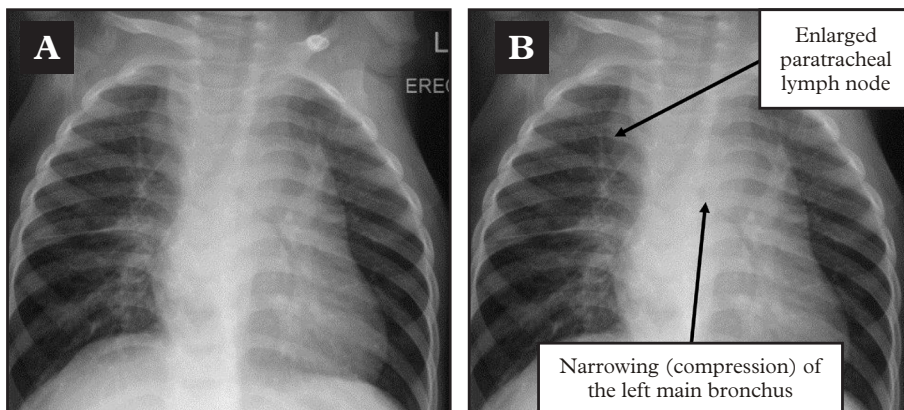


Figure 5.22 CXR B is an annotated version of CXR A, an AP CXR taken from a 3-year-old child. There is an enlarged right paratracheal lymph node that has caused the trachea to shift to the left. There is also narrowing of the left main bronchus – this is caused by enlarged hilar (including sub-carinal) lymph nodes compressing the airway. The lymph nodes themselves are not always easy to see (as is the case with the perihilar lymph nodes in this CXR).

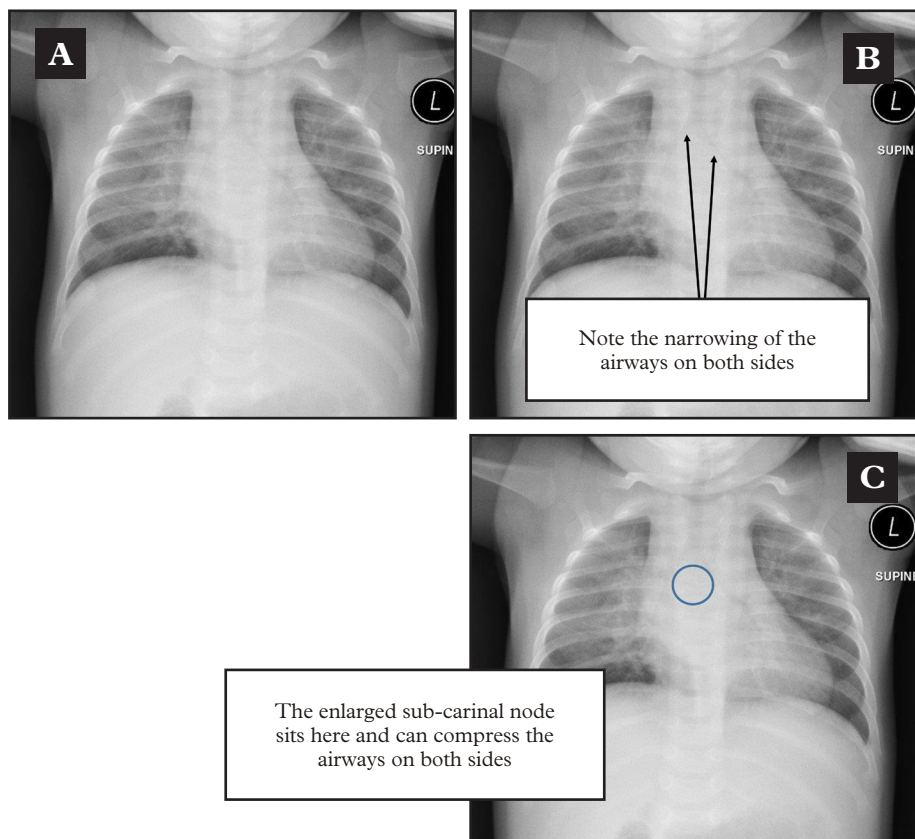


Figure 5.23: CXR A, B and C are all the same AP CXR, taken from a 1-year-old child. This CXR shows bilateral airway narrowing (annotated in CXR B). You can see the impression of an enlarged sub-carinal lymph node annotated as the circle on CXR C. This is radiologically severe disease because there is large airway involvement

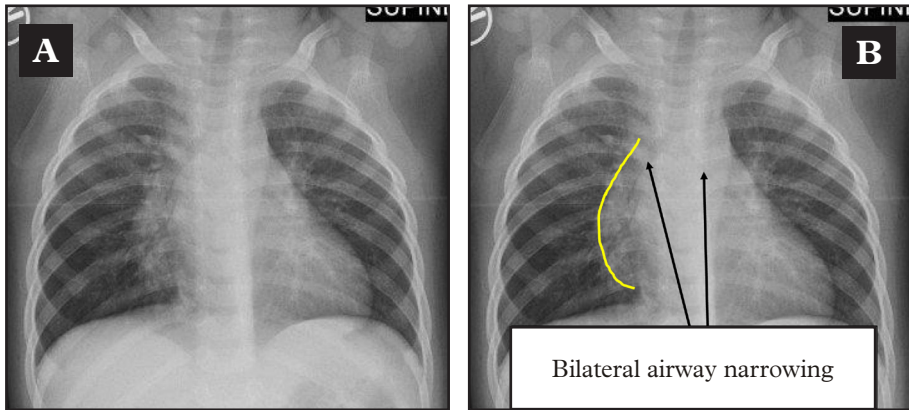


Figure 5.24: CXR B is an annotated version of the CXR A which is an AP CXR taken from a 3-year-old child. Note that the right hilum appears full with an opacity that bulges outwards - this is suggestive of an enlarged right hilar lymph node. What is more obvious is the narrowing of the airways bilaterally (bronchus intermedius on the right and left main bronchus on the left) - there are enlarged perihilar (including sub-carinal) lymph nodes pressing on the airways. This is radiologically severe disease.

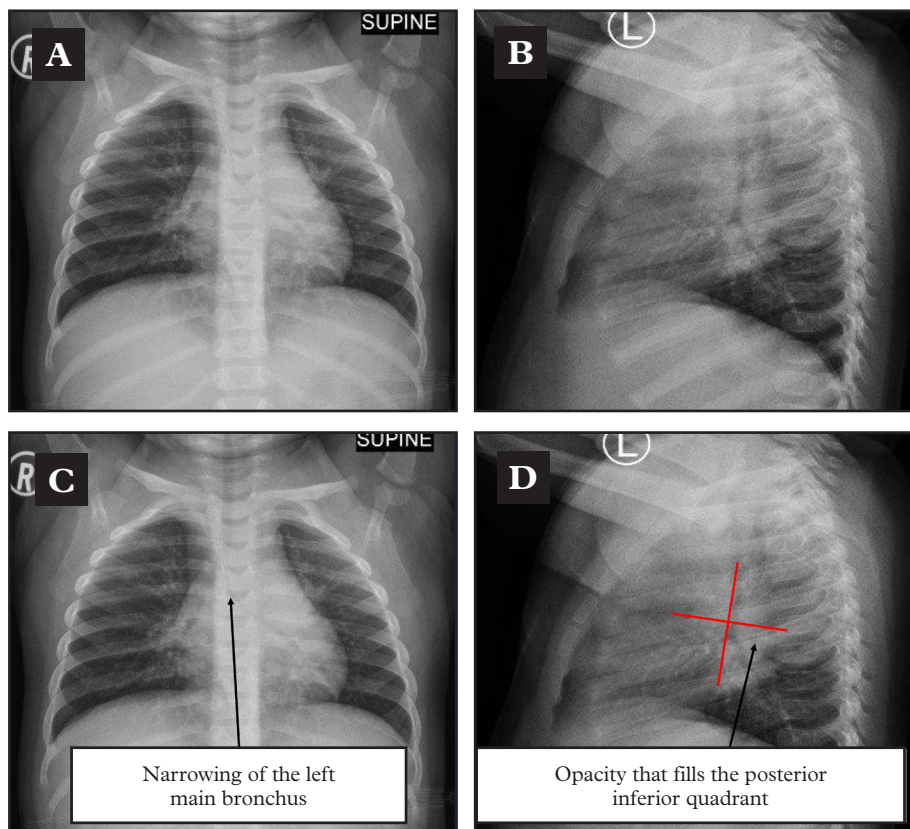


Figure 5.25: CXR A and B are a set of AP and lateral CXRs taken from a 2-year-old child. CXR C and D are the same set of CXRs but these are annotated. Enlarged lymph nodes are not obvious on the AP films, but there is narrowing of the left main bronchus. The enlarged lymph nodes are more apparent on the lateral film – note how the opacity on the lateral CXR includes the posterior inferior quadrant space. This is radiologically severe disease because there is airway compression.

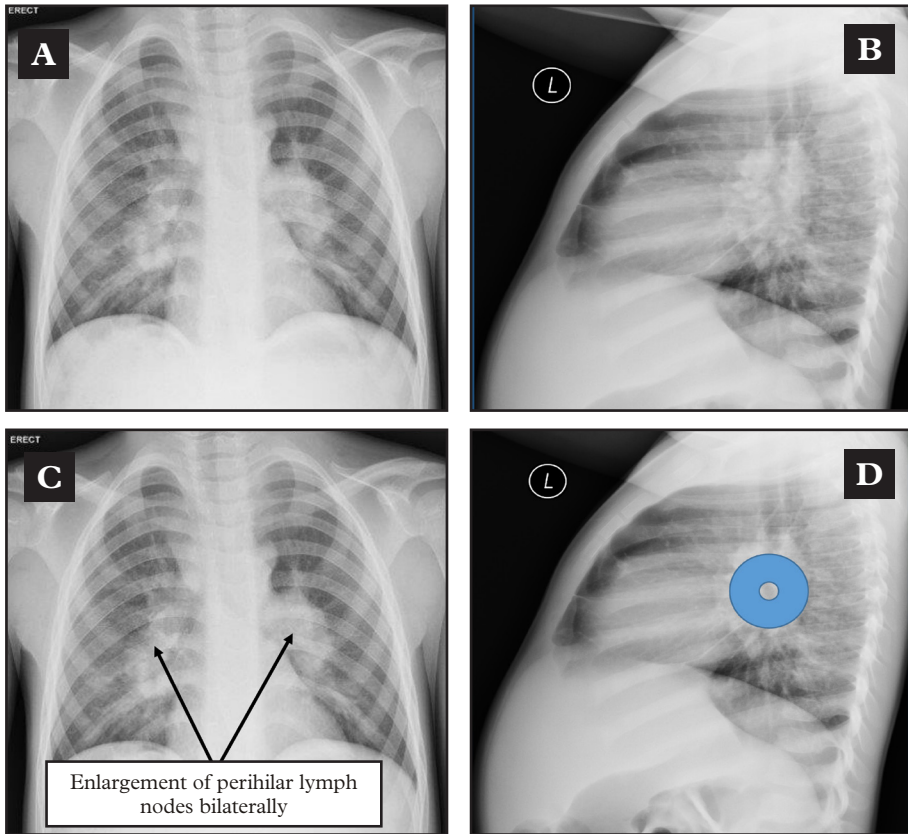


Figure 5.26: CXR A and B are a set of AP and lateral CXRs from a 6-year-old child which show bilateral enlargement of hilar lymph nodes. CXR C and D are the same set of CXRs, but these are annotated. On the AP films (CXR A and CXR C) note the lobulated / round opacities in both hilar regions. There is also bilateral airway compression. On the lateral film (CXR B and CXR D) you can see the doughnut / hamburger sign - the annotated abnormal opacity in the inferior posterior quadrant. This is radiologically severe disease because there is airway compression.

Unilateral hyperinflation

As the bronchus starts to narrow due to the airway compression, a point is reached where the narrowing acts as a “check valve”. This allows air to enter the affected lobe or lung but does not allow it to exit. This causes the air to be trapped and can be seen on CXR as unilateral hyperinflation of the lung or lobe with decreased vascularity (basically, the lung appears darker). This is an uncommon radiological presentation of TB. The commonest cause of unilateral hyperinflation in a young child (<3 years) is foreign body aspiration, which usually presents more acutely.

On clinical examination, the affected lung is hyperinflated (loss of cardiac dullness and diaphragms displaced downwards) with decreased air entry on auscultation on the side of the hyperinflation. The radiological picture is that of a hyperinflated enlarged lung or lobe with decreased vascularity - make sure the CXR is not just rotated!

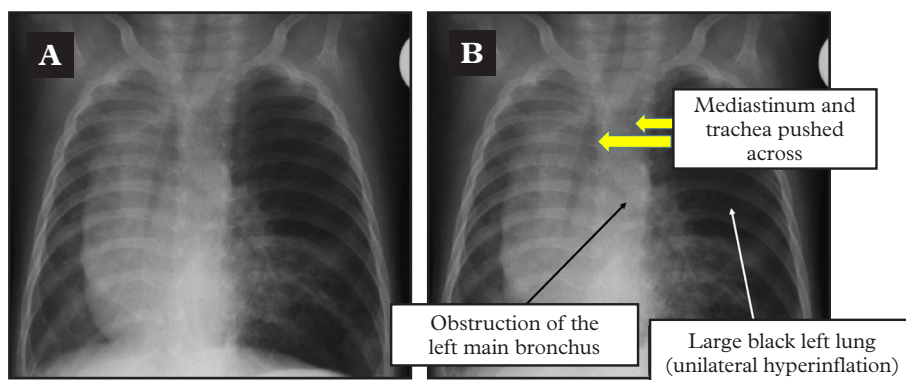


Figure 5.27: CXR B is an annotated version of CXR A. This CXR shows obstruction of the left main bronchus causing a “check valve” effect with hyperinflation of the left lung. Because the airway is only partially obstructed air can enter the left lung and is herniating across to the right but cannot exit – the left lung is enlarged with decreased vascularity and the mediastinal structures are pushed across to the right.

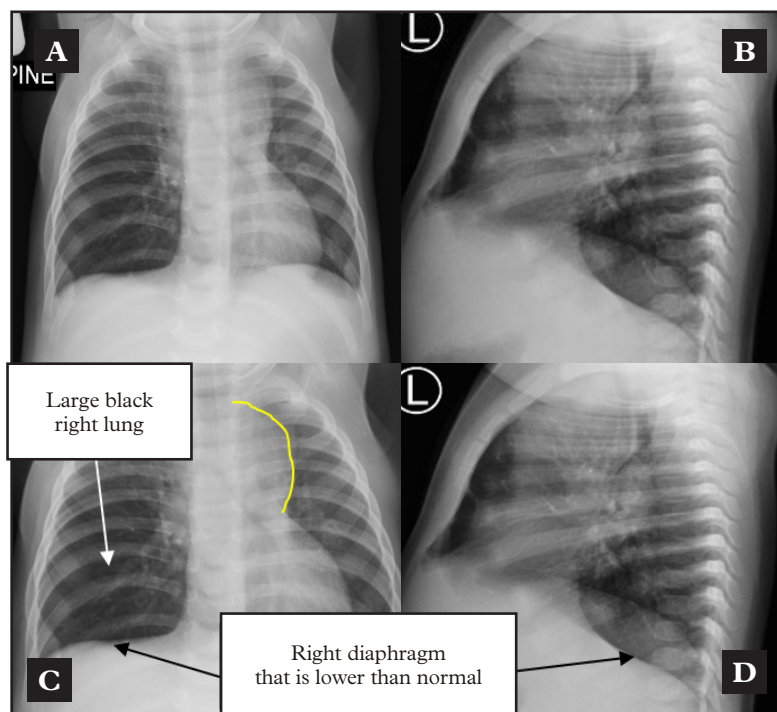


Figure 5.28: CXRs C and D are annotated versions of CXRs A and B that were taken from a 4-year-old child. Note that the right lung appears larger than the left and has decreased vascularity. The right diaphragm is lower than the left when it should be higher and is very flat. The mediastinal structures are pushed across to the left. There is air in front of the heart on the lateral film due to herniation of the right lung across the mediastinum. This is caused by partial obstruction of the right main bronchus/bronchus intermedius and hyperinflation of the right middle and lower lobes: check valve effect. This is radiologically severe disease.

Lobar or segmental collapse

When the lymph node compression completely obstructs the airway collapse of the segment or lobe can occur. This is not a common CXR pattern and care should be taken not to miss other causes of collapse, such as foreign body aspiration (usually an acute clinical presentation) or mucus plugs secondary to viral respiratory tract infections. The commonest lobes that are affected in pulmonary TB are the right middle lobe or the lower lobes.

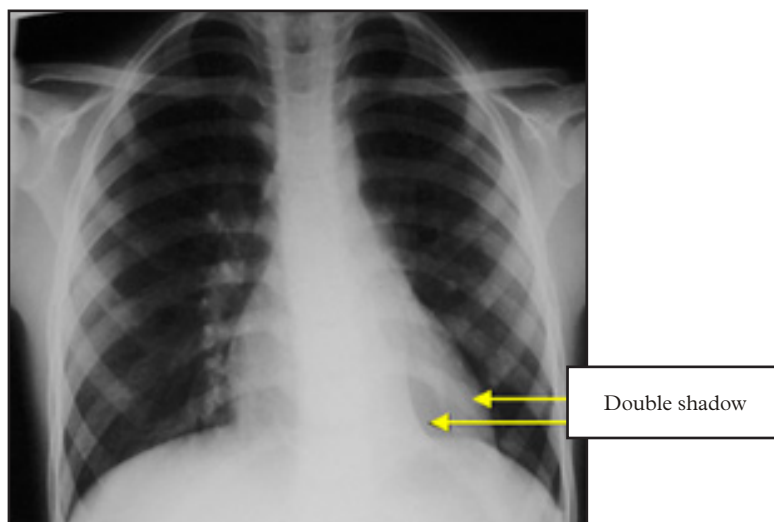


Figure 5.29: This CXR was taken from an 8-year-old child and shows left lower lobe collapse with the double shadow seen through the cardiac shadow. The left main bronchus can in some cases be seen running down at a more acute angle than usual, though not seen in this radiograph.

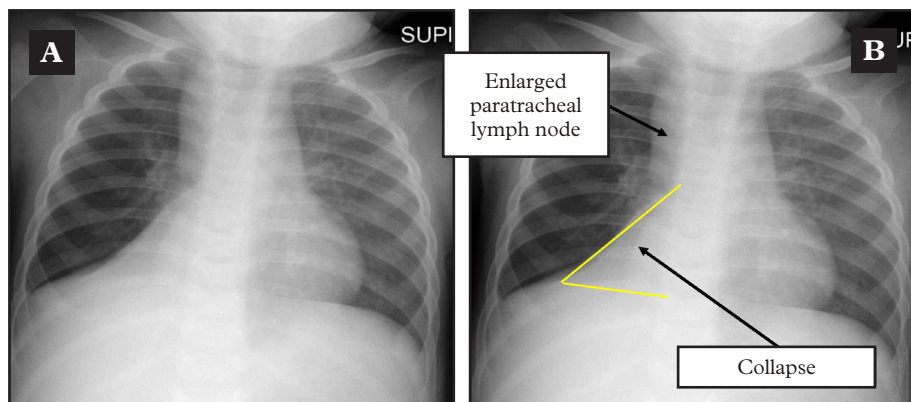


Figure 5.30: CXR B is an annotated version of CXR A which was taken from a 2-year-old child. This CXR shows collapse of the right middle lobe and right lower lobe due to lymph node compression of the bronchus intermedius. Note the large right paratracheal lymph node which is pushing the trachea to the left.

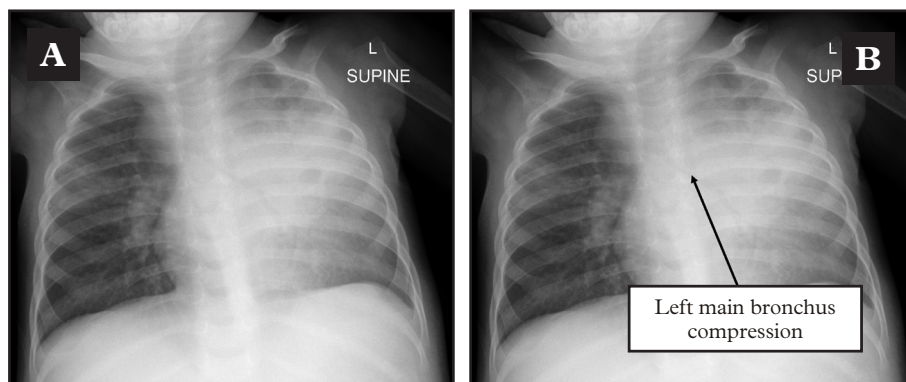


Figure 5.31: CXR B is an annotated version of CXR A showing dense lobar opacification of the left upper lobe with narrowing of the left main bronchus. This CXR nicely demonstrates how the effect of enlarged lymph nodes can be seen on the CXR (narrowing of the airway) even though the lymph nodes may not be clearly seen. A lateral film would have been helpful here. This is radiologically severe disease.

Complicated lymph node disease is the result of enlarged lymph nodes narrowing, obstructing or ulcerating into the large airways.

5.2.3 Pleural disease

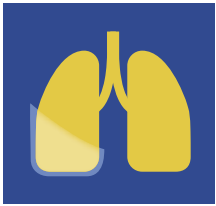





Pleural involvement in paediatric TB is classified as extra-pulmonary. Pleural disease is included in this Atlas because it is most commonly identified using a CXR. There are several pathophysiological processes that can cause pleural effusion in paediatric TB.

The most frequent process is from direct spread from a sub-pleural primary (Ghon) focus which causes a hypersensitivity reaction and the formation of a transudative, straw-coloured effusion. There are few organisms and samples from the effusion are normally both XpertMTB/RIF and culture negative. These effusions are usually simple and large and are most commonly seen in older children and adolescents – this is classified radiologically as non-severe disease. If the pleural effusions are large, they may cause mediastinal shift on CXR. These children and adolescents normally present with fever and gradual onset of shortness of breath and sometimes chest pain.

Pleural effusions from direct spread can also be empyemas. This means that the fluid is an exudate and is comprised of caseous material that usually contains many organisms and is more likely to be XpertMTB/RIF and/or culture positive. These empyemas are usually smaller and often appear as complicated pleural effusions with other associated abnormalities on CXR.

It is difficult to distinguish TB pleural effusions from other causes of pleural effusions on CXR alone. You need to correlate the CXR findings with the clinical presentation. Children with pleural effusions caused by bacteria other than *M.tb* (such as pneumococcus and staphylococcus) are usually younger and more acutely unwell than children with TB effusions.

Complicated pleural effusions, compared to simple effusions, include effusions which are loculated and/or associated with parenchymal disease and are classified as radiologically severe disease. TB pleural disease in children also includes pleural thickening which occurs when pleural fluid has become organised.

Simple pleural effusion 		Fairly common
		Specific
	NON-SEVERE	Non-severe
Complicated pleural effusion 		Uncommon
		Specific
	SEVERE	Severe

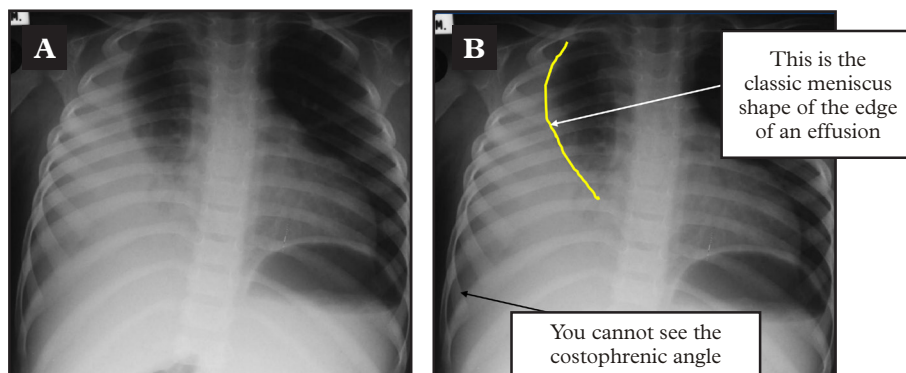


Figure 5.32: CXR B is an annotated version of CXR A, taken from a 6-year-old child. It shows a simple right-sided pleural effusion with no other radiological features of TB visible and no obvious parenchymal involvement. Note the classic meniscus shape of the effusion edge, which slopes downwards medially. This is a simple pleural effusion which is classified as non-severe radiological disease. This CXR pattern is more common in older children and adolescents.

In a high TB-burden setting the commonest cause for a large pleural effusion in an adolescent is TB.

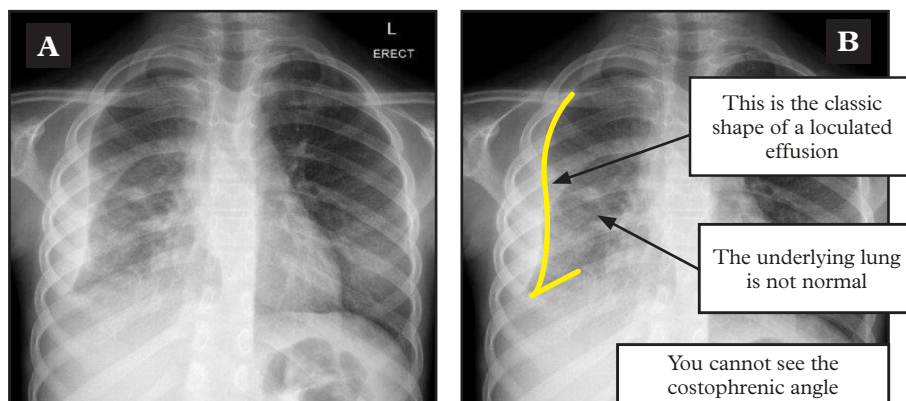


Figure 5.33: CXR B is an annotated version of CXR A and shows a right-sided loculated effusion with underlying lung disease. This is radiologically severe disease.

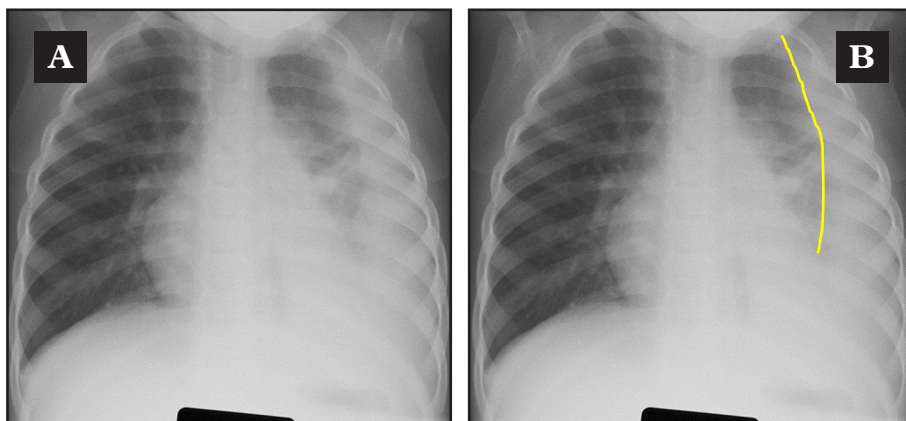


Figure 5.34: This CXR was taken from a 7-year-old child. CXR B is the same as CXR A but the edge of the effusion is annotated. This is a left-sided pleural effusion. There is also underlying lung parenchymal disease (the underlying lung appears whiter). This is radiologically severe disease.

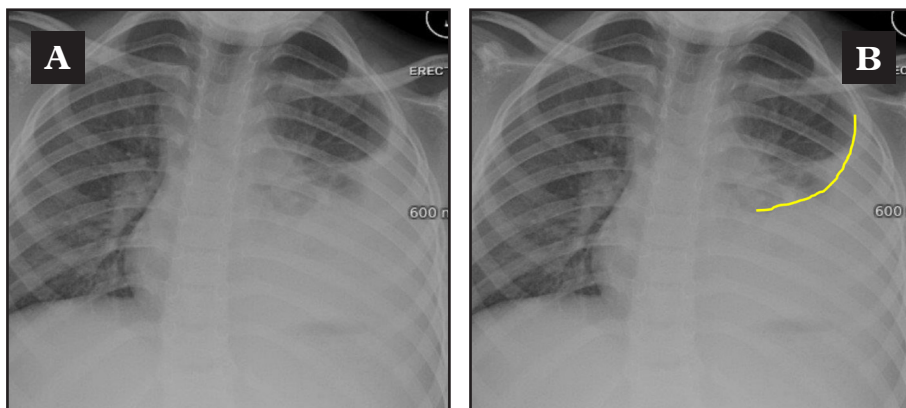


Figure 5.35: This CXR, from a 3-year-old child, shows a large simple pleural effusion on the left. Note the meniscus shape of the edge of the effusion annotated on CXR B (CXR A is a clean version of the same CXR). This is radiologically non-severe disease because there is no loculation, no significant mediastinal shift and because the underlying lung parenchyma that can be seen looks normal.

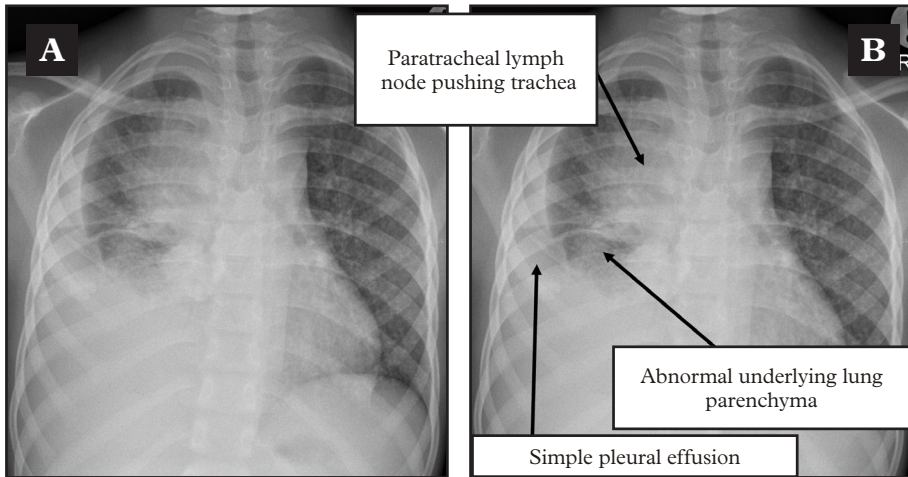


Figure 5.36: CXR B is an annotated version of CXR A showing a right-sided pleural effusion with underlying lung parenchymal involvement, right-sided paratracheal lymph node and tracheal deviation. This is radiologically severe disease because the effusion is associated with underlying parenchymal involvement of the lung and there is large airway involvement.

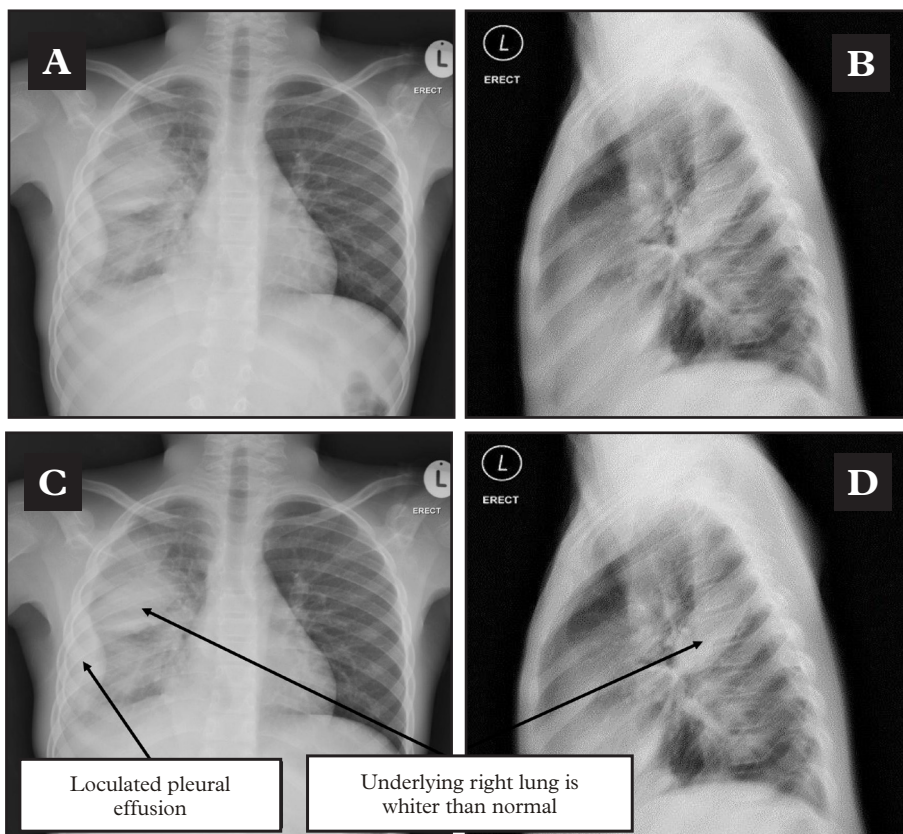
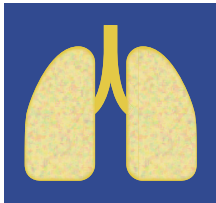





Figure 5.37: The set of CXRs A and B are the same as the set of CXRs C and D, but CXRs C and D are annotated. These CXRs were taken from an 8-year-old child and they show a right-sided loculated pleural effusion. Note the opacification that tracks the pleura on the right. This is the classic shape of a loculated pleural effusion. The underlying lung parenchyma on the right is not normal (whiter than usual). This is due to likely alveolar opacification “consolidation” in that lung. This is radiologically severe disease.

5.2.4 Miliary disease

Miliary disease 		Uncommon
		Very specific
		Severe

If a large number of organisms enter the blood vessels from the mediastinal lymph nodes (either directly or via the lymphatic duct), then they can disseminate haematogenously to involve other organs. When spread to the lungs in this way, a pattern known as ‘miliary TB’ can develop. As the nodules are all similar in size, they are seen on CXRs as evenly distributed, small, millet-sized (less than 2 mm), round opacities. They are often best observed on the lateral chest radiograph in the lower lobes (posterior to heart). If untreated, the nodules get larger as the disease progresses, and they can be difficult to differentiate from bronchopneumonic opacification. Miliary TB is classified as extra-pulmonary disease but is included in this Atlas as it is usually diagnosed on CXR. The radiological picture of miliary TB can occur with or without other radiological features of primary TB being visible. These children are clinically ill and often have accompanying TB meningitis or multiple tuberculomas.

If this pattern is seen in an HIV-positive child not on ART, miliary TB can be difficult to distinguish from lymphocytic interstitial pneumonitis (LIP). Given improved access to ART, LIP is now less commonly seen. Clinically, children with LIP are older and less acutely ill than children with miliary TB and may have bilateral enlargement of the parotid glands and digital clubbing. If there is accompanying central nervous system involvement, or if the child is <1 year old, the most likely diagnosis is miliary TB.

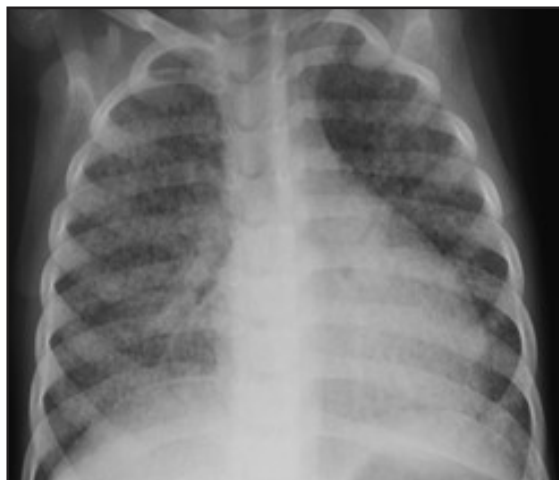

Figure 5.38: This CXR shows fine millet-sized nodules typically seen in miliary TB. The nodules are all of similar size and evenly spread throughout both lung fields. No other radiological signs of primary TB are visible. This is radiologically severe disease.

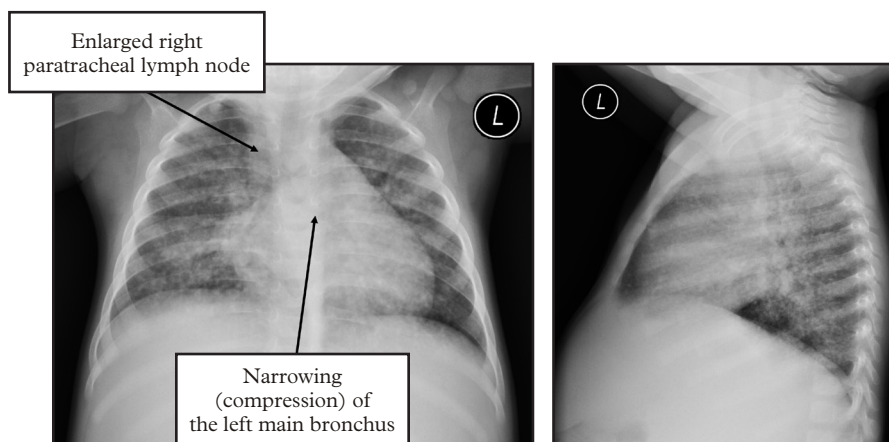


Figure 5.39: This CXR shows miliary infiltrates similar to those described in Figure 5.38. There is also an enlarged paratracheal lymph node on the right and the left main bronchus appears narrowed.

5.2.5 Cavitory disease

<div>Cavitory disease</div> 		Uncommon
		Very specific
	<div>SEVERE</div>	Severe

Although the typical cavitory CXR pattern in paediatric TB is that of post-primary adult-type disease, cavities can also develop in primary TB.

Primary progressive TB

Cavities can develop in primary TB when: a primary (Ghon) focus enlarges and develops central necrosis, or a hilar lymph node perforates into an airway causing endobronchial aspiration of bacilli and local areas of caseation seen as consolidation on CXR. It can be either dense segmental or lobar consolidation or patchy consolidation surrounding the airways.

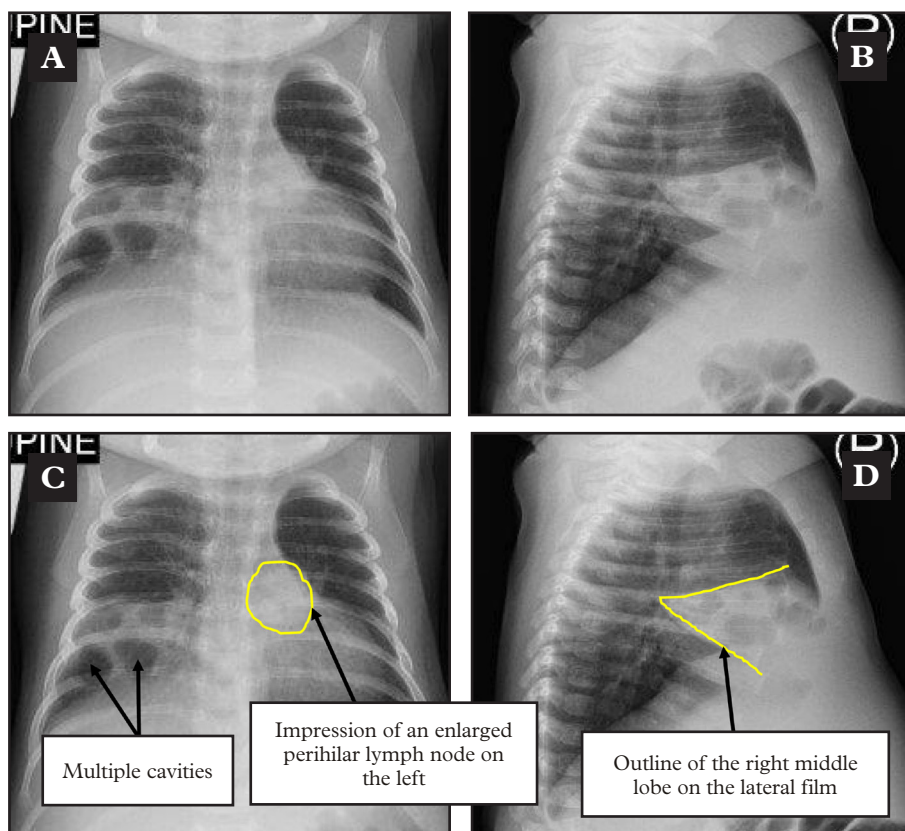


Figure 5.40: CXRs A and CXR B are a set of AP and lateral CXRs taken from a 3-year-old child. CXRs C and D are the same set of CXRs but they are annotated. Note the right middle lobe opacification with breakdown (cavity formation). There is possibly an enlarged left hilar node visible but it is not obvious. This is radiologically severe disease.

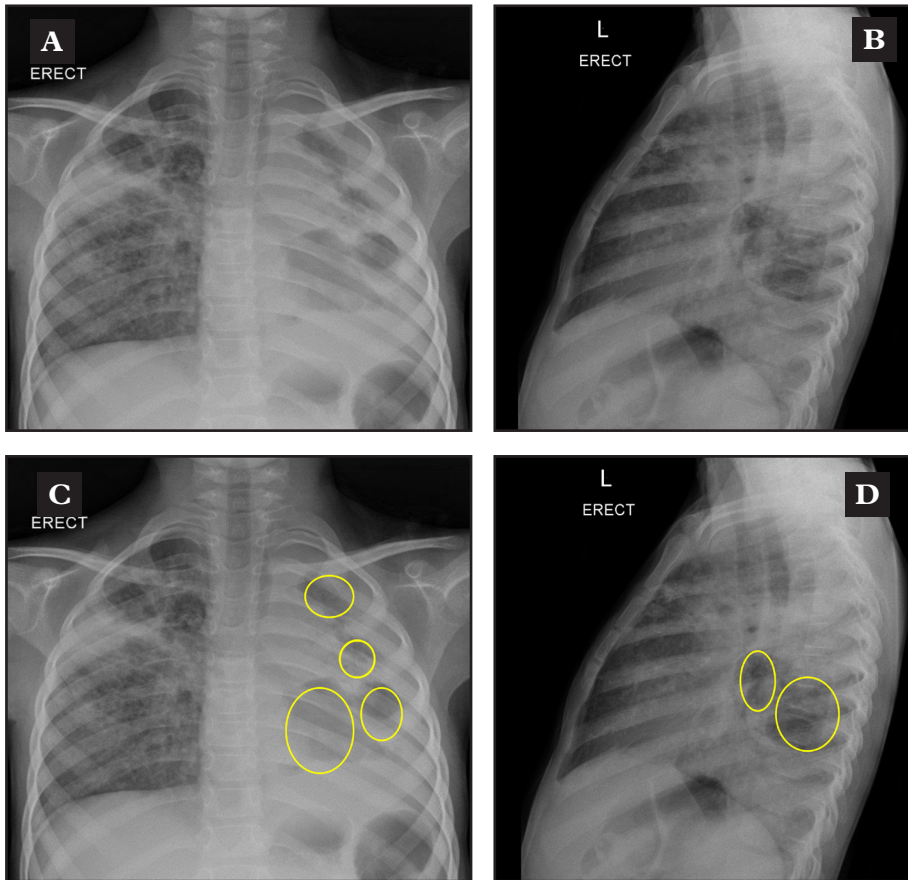


Figure 5.41: CXRs A and B are a set of PA and lateral CXRs taken from a 9-year-old child. There is widespread bronchopneumonia present (bilateral patchy opacities throughout the lungs) with cavities in both lungs. This is primary progressive disease. CXRs C and D are the same set of CXRs but these are annotated to outline some of the cavities. This is radiologically severe disease.

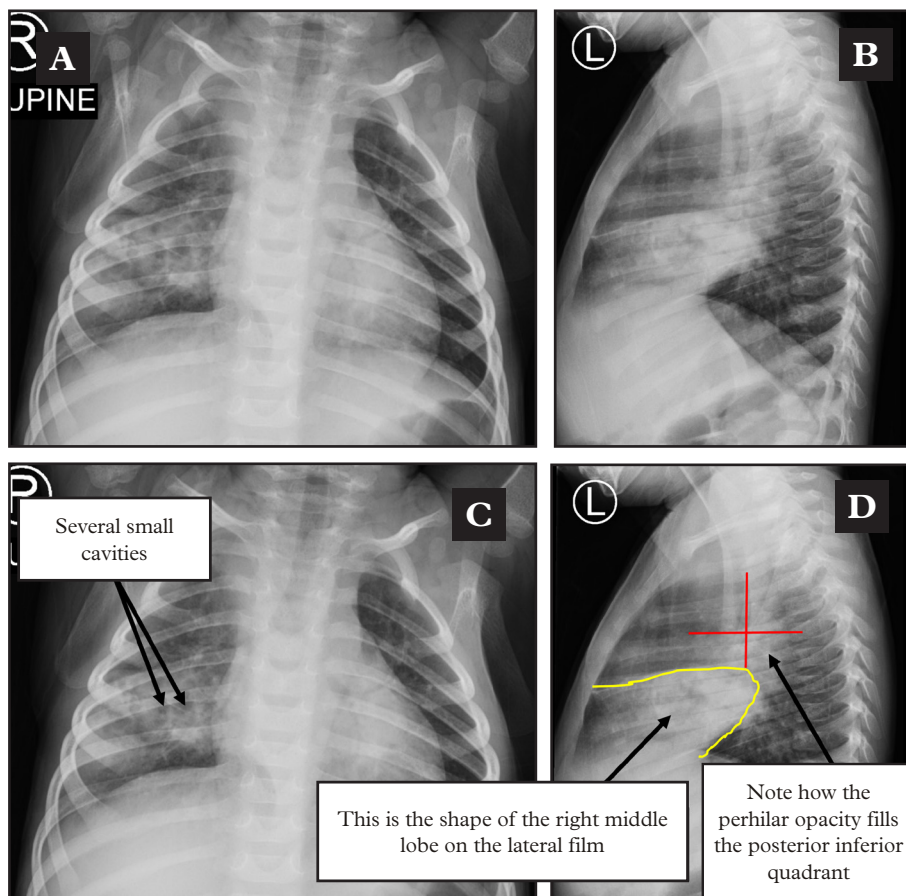


Figure 5.42: CXRs A and B and CXRs C and D are the same set of CXRs - AP and lateral films taken from a 4-year-old child. These CXRs show bronchopneumonic changes in the right middle lobe with cavity formation. There are enlarged perihilar nodes (more clearly seen on the lateral film) and compression of the bronchus intermedius on the right. There is also a right paratracheal lymph node. This is primary progressive disease and is classified radiologically as severe because there are cavities and there is airway compression.

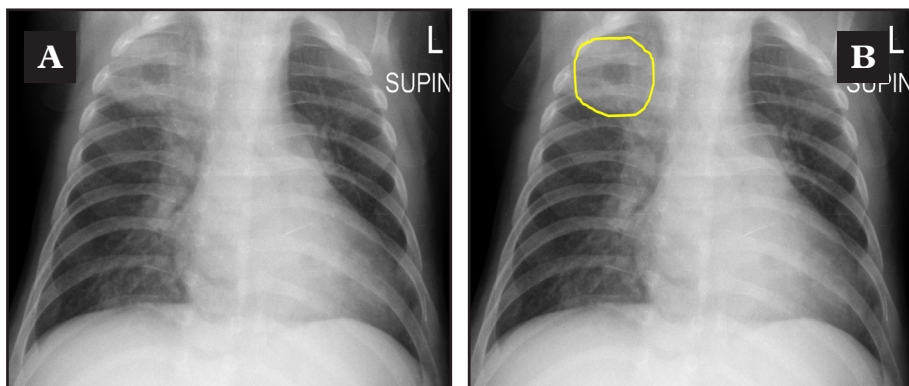


Figure 5.43: CXR B is an annotated version of CXR A and shows a cavitating primary (Ghon) focus in the right upper lobe. The left main bronchus also looks narrow. This is radiologically severe disease.

Adult-type (post-primary) TB

The most classic cavitory CXR pattern in paediatric TB is that of adult-type (post-primary) TB disease. This is seldom seen in children younger than 10 years. It occurs at a younger age in girls than it does in boys and presents with the same clinical and radiological picture as TB in adults. Respiratory samples are likely to be positive for *M. tb* on smear, XpertMTB/RIF and culture.

The involvement, as in adults, is usually in the upper lobes or the apices of the lower lobes. Early in the course of the disease, there is vague opacification in the upper lobes which has been termed “smudge or cotton wool lesions”. As the disease progresses, the lesions become more dense, parenchymal breakdown occurs and cavities develop (Figure 5.44 and 5.45). The cavities typically have no air-fluid levels and may be bilateral. These lesions mostly heal by fibrosis, leading to fibrotic upper lobes though this does not happen always.

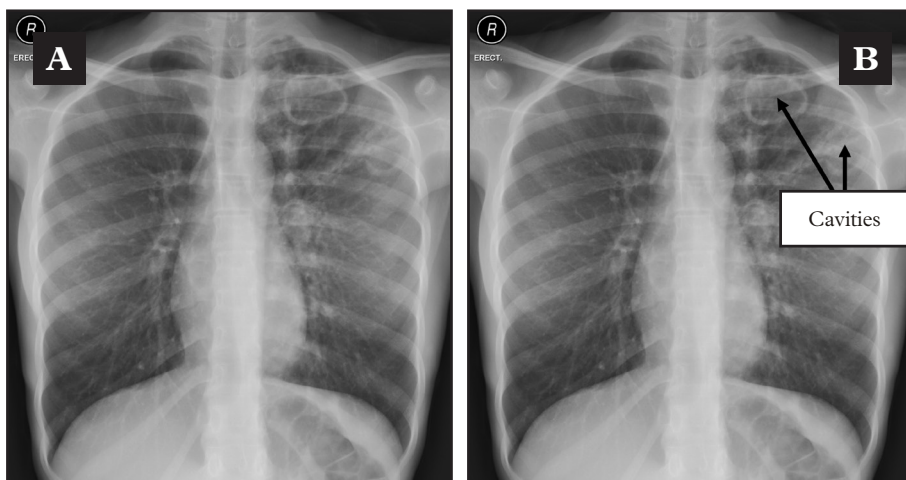


Figure 5.44: This PA CXR was taken from an 11-year-old child. This CXR (CXR A is clean and CXR B is annotated) shows cavities in the left upper lobe. In adult-type disease cavities are typically seen in the upper lobes and apices of the lower lobes.

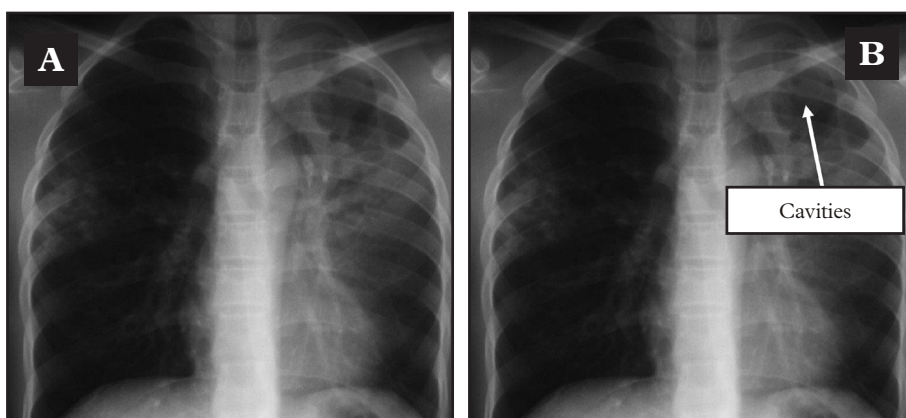


Figure 5.45: CXR B is an annotated version of CXR A. This CXR shows a case of post-primary TB in a 10-year-old child. Cavities are present in the left upper lobe. This patient was sputum smear positive. This CXR is over-penetrated.

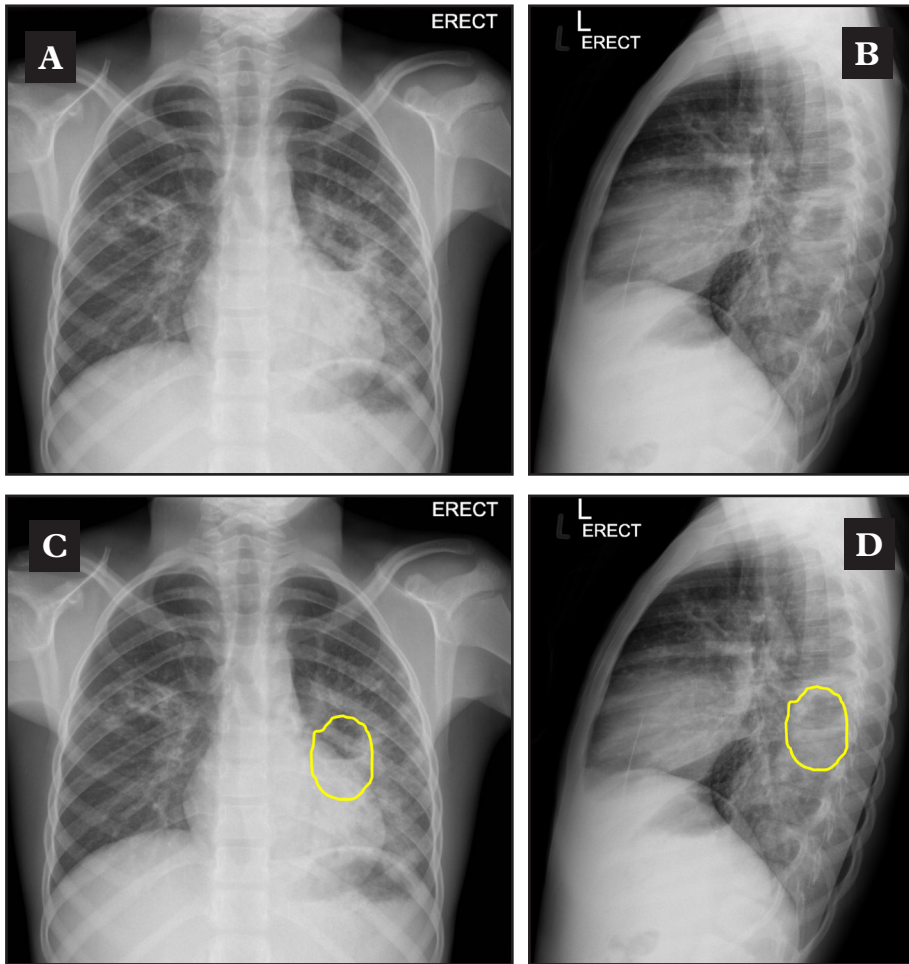
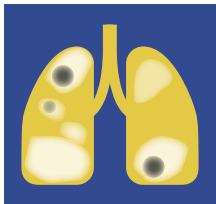





Figure 5.46: CXRs A and B are a set of CXRs taken from a 9-year-old child. CXRs C and D are the same set of CXRs but are annotated to show the cavity in the left lower lobe with bronchopneumonic infiltrates in both lungs. This is radiologically severe disease.

5.2.6 Other uncommon CXR patterns

TB bronchopneumonia

TB bronchopneumonia 		Very uncommon
		Very specific
		Severe

TB bronchopneumonia can occur if either a lymph node or a cavitating lung lesion ulcerates through the wall of a bronchus and causes aspiration of tuberculous material into the lung parenchyma and throughout the lung. The CXR pattern can be difficult to distinguish from miliary TB, as both cause bilateral, widespread disease. In TB bronchopneumonia the lung lesions are larger (coalesced) and small cavities within the lesions are often present. These small cavities are sometimes difficult to see on CXR and can be missed.

TB bronchopneumonia is an uncommon CXR pattern and is usually seen in combination with other abnormal CXR features which have high specificity for TB, such as enlarged lymph nodes, airway involvement, pleural effusions and cavitary disease. This means that, even if you are not sure whether the CXR shows TB bronchopneumonia, you will likely see the other specific features of TB and the extensive parenchymal involvement and you will manage the child correctly.

These children are usually acutely ill and they often require supplementary oxygen and antibiotic treatment.

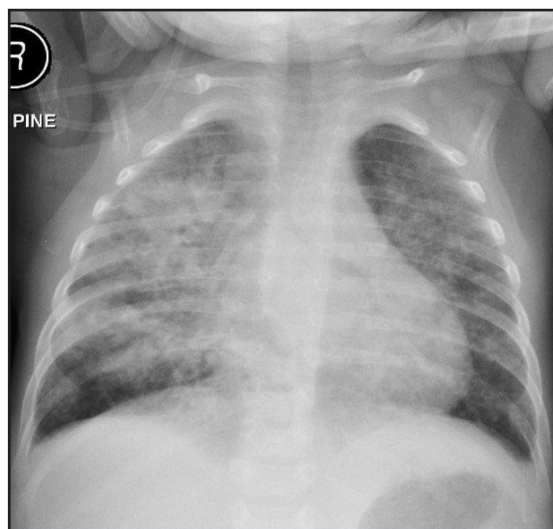

Figure 5.47: This CXR shows TB bronchopneumonia in an infant. Note the patchy opacifications which are widespread throughout both lungs and the areas of breakdown (cavity formation), predominantly on the right. There is also compression of the left main bronchus and likely an enlarged sub-carinal lymph node. This is radiologically severe disease.

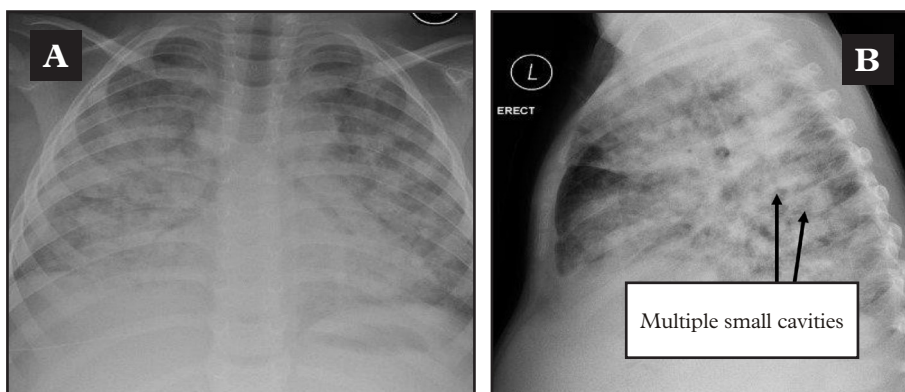


Figure 5.48: This AP and lateral CXR was taken from a 1-year-old child and is a case of TB bronchopneumonia. There are extensive patchy opacifications throughout both lungs with areas of breakdown (cavity formation).

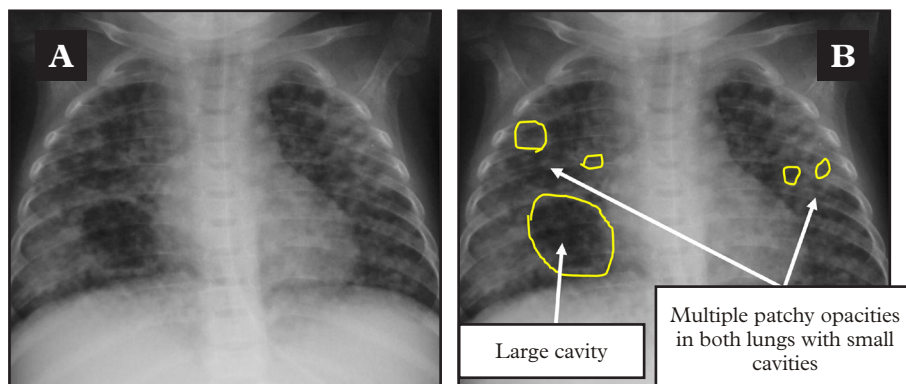
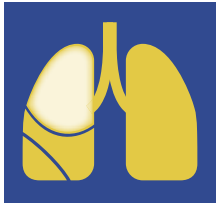




Figure 5.49: This CXR shows another case of TB bronchopneumonia (CXR A is clean and CXR B is the same CXR but annotated). Note the bilateral, widespread involvement of the lung parenchyma with patchy opacities that are larger than those seen in miliary TB. There are multiple small areas of breakdown (cavities) as well as a large cavity in the right middle lobe. This is radiologically severe disease.

Expansile pneumonia

Expansile pneumonia 		Very uncommon
		Very specific
	SEVERE	Severe

If a lymph node ulcerates through the bronchus wall, it can cause occlusion of the bronchus and aspiration of infected material into the lung parenchyma. The immunological response to the aspirated tuberculous material may cause dense opacification and expanding size of the involved lung segment or lobe. This process leads to expansion in the size of the lobe or lung and upward or downward displacement of the fissures which can be seen on CXR as a densely consolidated lobe or lung, without any visible air bronchograms; the lobe or lung is increased in size and a “bulging fissure” can often be seen. Expansile pneumonia

is most often seen in the upper lobes. Airway compression is common but the lymph nodes are seldom seen as they are hidden by the densely opacified lobe. The mediastinum can be pushed across to the opposite (unaffected) side. As the process proceeds, necrosis of the lobe occurs, and cavities can develop. Expansile pneumonia represents severe TB disease.

Expansile pneumonia is more common in young children who usually present acutely ill with increased work of breathing, swinging fevers and non-resolving pneumonia. If airway compression is seen or suspected, steroid therapy may be required. The CXR lesions resolve with treatment but may result in a small fibrotic lobe or, in a minority of patients, bronchiectasis of the affected lobe.

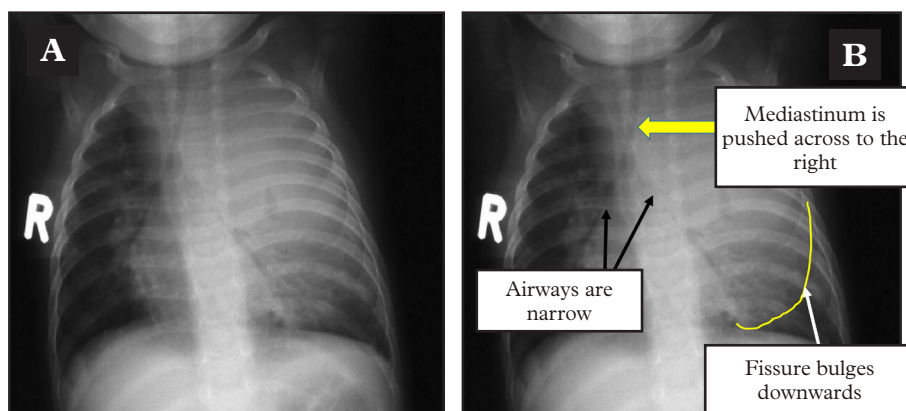


Figure 5.50: This CXR was taken from a 1-year-old child. CXR B is an annotated version of CXR A which shows expansile pneumonia of the left upper lobe. Note that there are no air bronchograms. There is also compression of the left main bronchus and the trachea, and mediastinum is displaced to the right. Note the features of an expansile process (increased volume) with area of breakdown on the left - the fissure bulges downwards and the mediastinum is pushed away from the abnormal side.

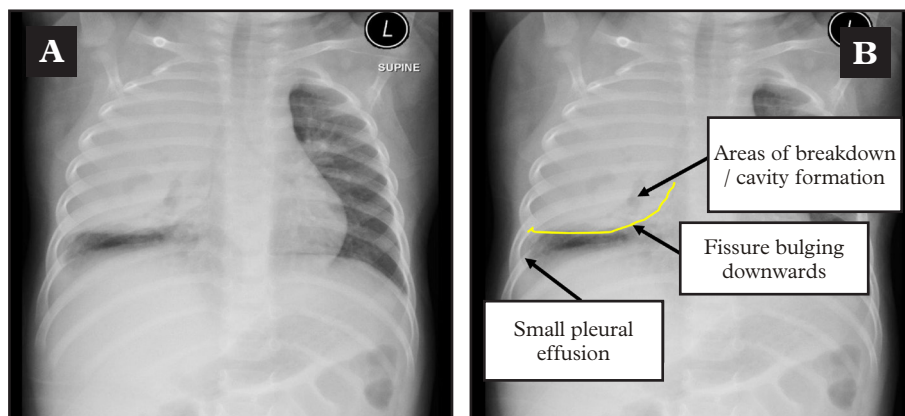



Figure 5.51: This CXR shows another case of expansile pneumonia in an infant. CXR B is an annotated version of CXR A. Note the horizontal fissure on the right bulging downwards which indicates an expansile process in the right upper lobe. There are no air bronchograms. There is compression of bronchus intermedius on the right. There is also a small pleural effusion on the right, as well as an area of breakdown (cavity formation) in the densely opacified lobe. This is radiologically severe disease.

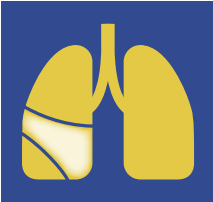



5.3 CXR features which are not very specific to paediatric TB

When interpreting the CXR from a child with presumptive pulmonary TB, the absence of the features described above (which have high specificity for pulmonary TB) does not exclude the diagnosis of TB. The less specific features described below should be interpreted in the context of the clinical presentation, household history of TB exposure and results of any specimens that were sent for TB microbiological tests. The decision may then be made to either treat for TB or to follow up closely (with or without antibiotic treatment) with repeat CXR in approximately 2 weeks.



Children with pulmonary TB often have non-specific CXR features. Always interpret the CXR findings within the full clinical context and remember the value of repeat imaging.

5.3.1 Alveolar opacification ("consolidation")

Alveolar opacification ("consolidation")  ≥ 1 lobe  < 1 lobe		Common
		Not specific
	SEVERE	≥ 1 lobe severe
	NON - SEVERE	< 1 lobe non - severe

Alveolar opacification (also called “consolidation” or “air-space disease”) is commonly seen in children with pulmonary TB. However, it is also seen in children with bacterial and, less commonly, viral pneumonia. “Co-infection” is also not uncommon, where children with underlying pulmonary TB present co-infected with a viral or bacterial pneumonia. Alveolar opacification is characterised as a dense, often homogeneous, confluent infiltrate in the lungs which may encompass an entire lobe (lobar opacification) or segment (segmental opacification), has a fluffy, mass-like, cloud-like density, erases heart and diaphragm borders (silhouette sign) and can contain air bronchograms.

Bronchopneumonia is another pattern of alveolar opacification: the opacities are not homogenous, are poorly defined and may involve several lobes; there may be associated peribronchial thickening. Bronchopneumonia as a general term is different to TB bronchopneumonia (described above) and can be caused by other viral and bacterial pneumonias.

Alveolar opacification can be seen in a child with pulmonary TB as the only abnormal feature on CXR or in combination with other CXR features. It is most commonly segmental (< 1 lobe) but can be lobar or bronchopneumonic. If there are no other CXR abnormalities seen then it is difficult, radiologically, to distinguish alveolar opacification caused by TB from that caused by bacteria or viruses. If alveolar opacification is the only abnormality on the CXR, it has poor specificity for TB. The clinical presentation is often helpful: children with alveolar opacification on CXR due to viral or bacterial pneumonia are usually acutely ill, breathing fast and may need supplementary oxygen while children with alveolar opacification on CXR due to pulmonary TB may appear quite well - “the CXR looks worse than the child”.

Alveolar opacification is commonly seen in children with pulmonary TB but, on its own, it does not distinguish pulmonary TB from bacterial or viral pneumonia.

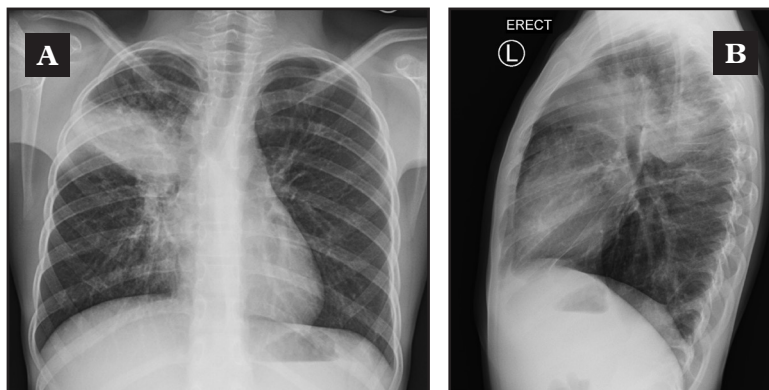
Segmental opacification

Figure 5.52: CXR A and B are a set of CXRs taken from a 5-year-old child. There is segmental opacification (this simply means that the opacification involves <1 lobe) of the right upper lobe. There might be an enlarged right hilar lymph node but it is difficult to see because of the opacity in the right upper lobe. This child could have pulmonary TB but could also have a viral or bacterial pneumonia. Correlate clinically! If the decision is made to treat for TB then this would be radiologically non-severe disease.

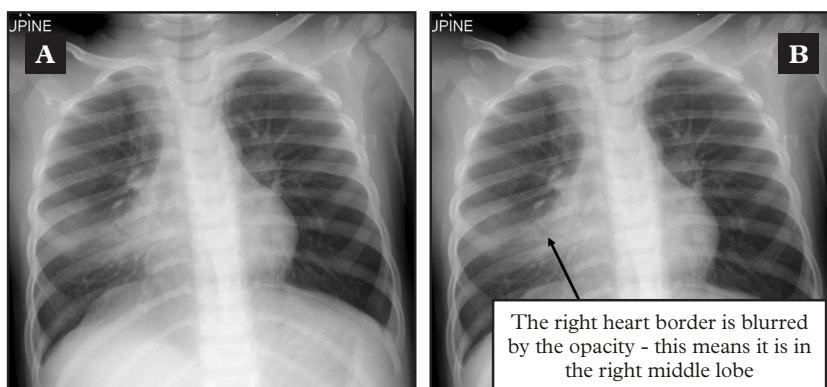


Figure 5.53: CXR B is an annotated version of CXR A which was taken from an 8-year-old child. This CXR shows segmental opacification (<1 lobe) of the right middle lobe (obscuring the right heart border). This could be pulmonary TB but could also be caused by a viral or bacterial pneumonia. If a decision is made to treat for TB this would be radiologically non-severe disease.

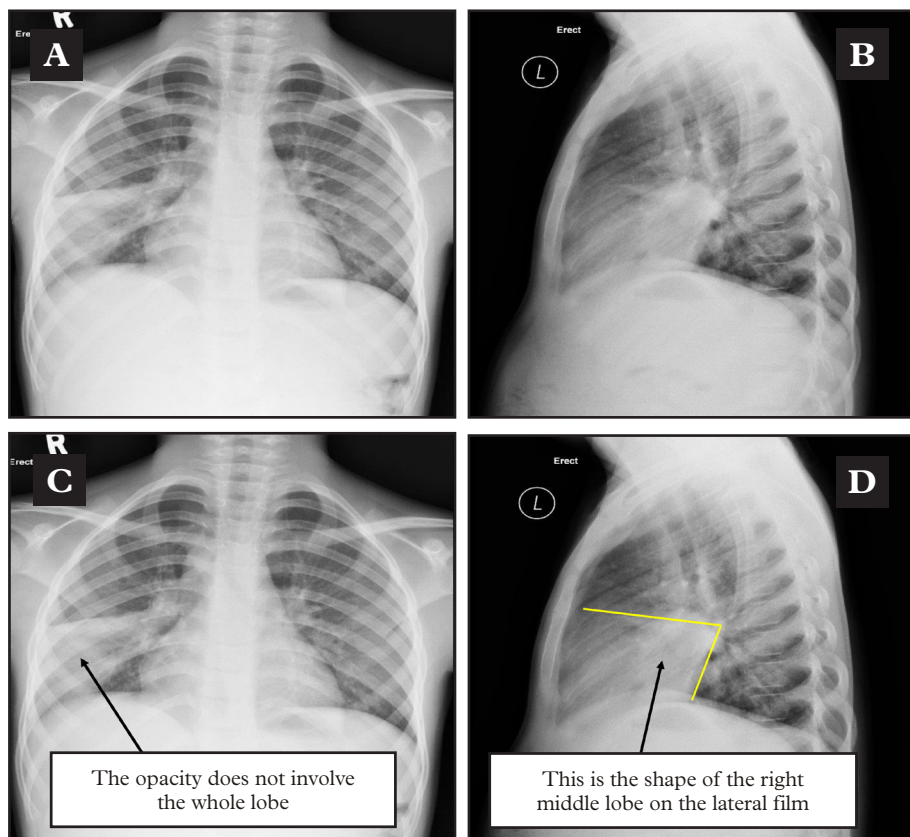


Figure 5.54: CXRs A and B are a set of AP and lateral CXRs taken from a 4-year-old child. CXRs C and D are the same set of CXRs with annotations. There is segmental opacification of the right middle lobe (this means that only a segment of the lobe is involved and not the whole lobe). This is non-severe radiological disease.

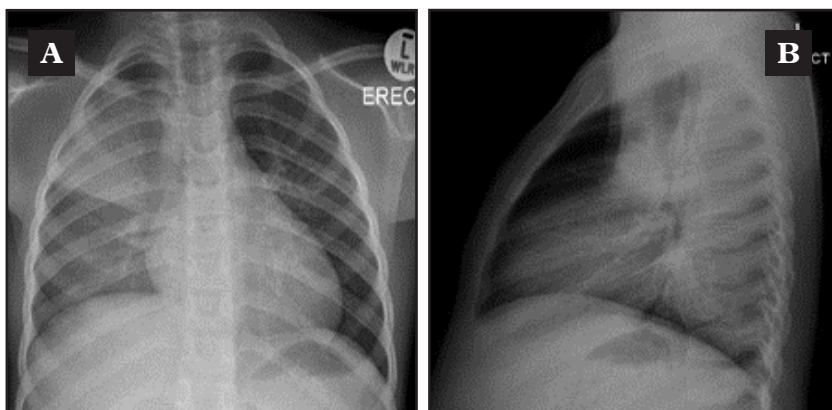


Figure 5.55: This set of AP and lateral CXRs shows segmental opacification of the right upper lobe. The horizontal fissure is clearly seen as a straight line on this film outlining the opacification of the right upper lobe. Note that the whole lobe is not involved - this makes the pattern segmental and disease radiologically non-severe.

Lobar opacification

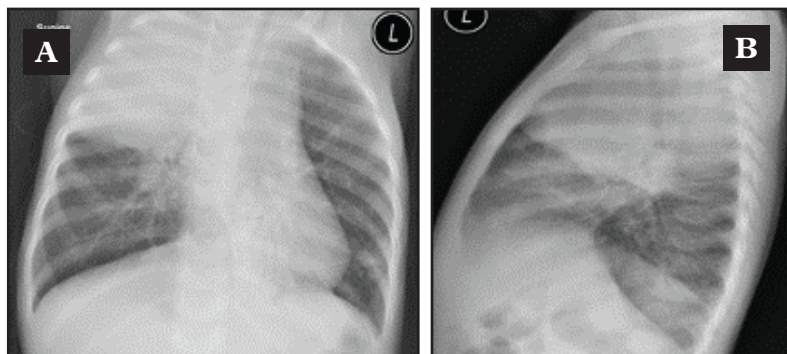


Figure 5.56: This CXR is a bit rotated which complicates interpretation of the mediastinal structures. If you compare this CXR to the previous one, you note that the entire lobe is involved here, whereas part of the lobe is spared in Figure 5.55. This CXR represents radiologically severe disease (≥ 1 lobe). Note that there could be enlarged lymph nodes present but it is not possible to see them due to the dense opacification.

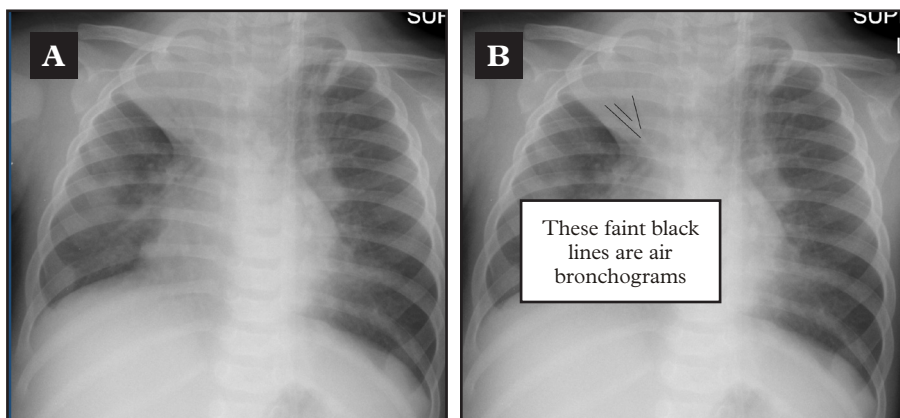





Figure 5.57: CXR B is an annotated version of CXR A which is an AP film from a 1-year-old child showing a right upper lobe pneumonia. Note the dense opacification that is solid, white and homogenous. One can see air bronchograms in the opacification. The horizontal fissure is pulled up suggesting that there is loss of volume in that lobe (consolidation/collapse). If the decision is made to treat for TB, this would be radiologically severe disease.

5.3.2 Other infiltrates

Perihilar infiltrates

Perihilar infiltrates 		Fairly common
		Not specific
	NON-SEVERE	Non - severe

The term ‘perihilar infiltrates’ refers to patchy areas of increased density (whiter than the normal air-filled lung tissue) in the perihilar areas of the lungs. These are usually present bilaterally and are restricted to the perihilar regions, that is, not seen in the outer two thirds of the lungs. Perihilar infiltrates are commonly

reported on CXRs from children treated for pulmonary TB but this is a non-specific term and does not help to distinguish TB from non-TB on CXR. This is also a common finding on CXR in children with viral respiratory tract infections.

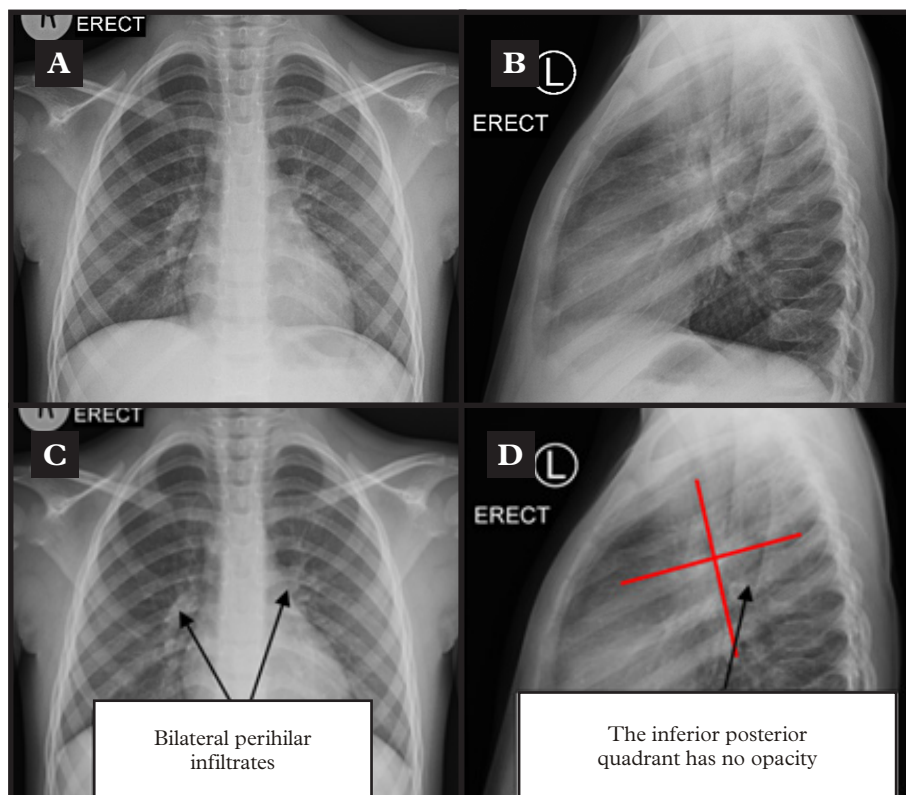






Figure 5.58: CXR A and B are a set of AP and lateral films taken from a 5-year-old child. CXR C and D are annotated versions of CXR A and B. Note the streaky infiltrates in the hilar regions bilaterally. These opacities are not round or lobulated which makes them less likely to be enlarged lymph nodes. There are no abnormal opacities seen on the lateral film – specifically no opacity in the inferior posterior quadrant.

Interstitial infiltrates

Interstitial infiltrates 		Uncommon
		Non - specific
		Non - severe

Interstitial infiltrates are characterised by linear/reticular, reticulonodular (stripes and dots) or patchy densities in the lung with peribronchial thickening. The term ‘dirty lungs’ is sometimes used. Interstitial infiltrates are typically bilateral. This is a non-specific CXR feature in children with pulmonary TB and is more commonly seen in children with viral lower respiratory tract infections. If an interstitial infiltrate is noted on a CXR from a child with presumed TB, care should be taken not to miss miliary infiltrates.

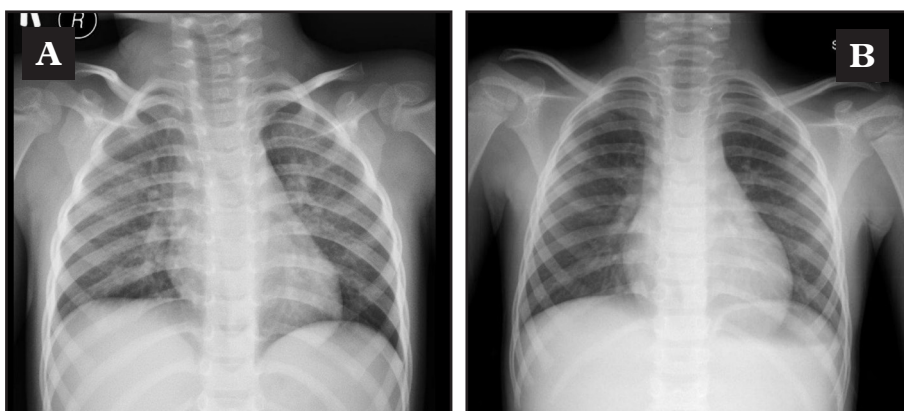


Figure 5.59: CXR A is another example of interstitial infiltrates. CXR B is normal. Compared to CXR B, note how the lung fields on CXR A look whiter (infiltrates) – there are small stripes/lines and dots throughout both lungs fields. This interstitial pattern is sometimes described as “dirty lung”. If the decision is made to treat this child for TB, this would be non-severe disease radiologically.

6 Approach to assessing radiological disease severity on CXR in paediatric TB


Until recently, the treatment of drug-susceptible TB disease in children consisted of a standard 6-month regimen, irrespective of the age of the child, HIV status or severity of disease. The exceptions were central nervous system TB and spinal TB, which were treated for 12 months and drug-resistant TB, which was treated for a longer duration and with second-line drugs. For several years, researchers have suggested that different types of TB disease represent different bacillary burdens and could be treated for different durations. In 2022, the SHINE (Shorter treatment for minimal TB in children) trial reported its findings. In this trial, children with non-severe TB disease and no known drug resistance were randomised to either receive 6 or 4 months of standard first-line therapy. For these children, 4 months was found to be non-inferior to 6 months of therapy. In other words, 4 months treatment was found to be as good as 6 months treatment. Disease severity was classified clinically, microbiologically and radiologically (using the CXR) on the trial.

In 2022 the WHO published their updated guidance on the treatment of TB children and, after reviewing the results of the SHINE trial, recommended the use of shorter treatment regimens for children with non-severe TB (see Text Box 6.1). This is why the algorithmic approach to CXR classification outlined in this Atlas includes an assessment of radiological disease severity.

Text Box 6.1: References for the WHO recommendation for shorter treatment for sub-groups of paediatric TB

- WHO consolidated guidelines on tuberculosis. Module 5: Management of tuberculosis in children and adolescents. World Health Organization, Geneva, 2022.
- WHO operational handbook on tuberculosis. Module 5: Management of tuberculosis in children and adolescents. World Health Organization, Geneva, 2022.

Assessing radiological disease severity on the CXR



You have now reviewed the CXR for:

1. Technical quality, and decided if it is
2. Normal or not normal, and whether it has
3. Features more specific or less specific for TB and after also reviewing the clinical and microbiological information, you have decided to treat the child for TB.

The next step is to decide whether the child has radiologically severe or non-severe disease as per recommendations in the WHO guidelines. Remember that disease severity is also classified clinically and microbiologically. Remember that not all children treated for TB will have specific CXR features so radiological disease severity is classified for CXR features that are both specific and less specific for TB.

Non-severe CXR features - see also Table 6.1

Non-severe radiological disease includes the presence of any of the following CXR features WITHOUT the presence of any of the severe CXR features:

- Uncomplicated lymph node disease
- Primary (Ghon) focus
- Alveolar opacification involving <1 lobe (bronchopneumonia confined to <1 lobe or segmental opacification)
- Simple pleural effusion
- Perihilar and/or interstitial infiltrates













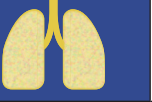

Severe CXR features

Severe radiological disease includes ANY of the following CXR features:

- Complicated lymph node disease
- Alveolar opacification involving ≥ 1 lobe
- Complicated pleural effusion
- All types of cavitary disease
- Miliary TB
- TB bronchopneumonia or expansile pneumonia

According to current guidance children with severe radiological manifestations of TB disease should not be considered for shortened TB treatment regimens. Children with non-severe disease may be treated for 4 months using standard first-line TB drugs at WHO recommended doses.

Children with severe CXR manifestations of TB may warrant referral for further investigations, such as bronchoscopy or computed tomography of the chest (CT chest). They may need adjunctive therapy to TB treatment, such as oral steroids. These children may also benefit from serial imaging and close clinical follow-up to TB treatment completion and beyond, as they are at higher risk of developing long-term respiratory morbidity.

Table 6.1: Classification of radiological disease severity on CXR	
Non-Severe	Severe
Uncomplicated lymph node disease	Complicated lymph node disease
	
Primary (Ghon) focus	Primary (Ghon) focus with cavitation
	
Simple pleural effusion	Complicated pleural effusion
	
Alveolar opacification: < 1 lobe	Alveolar opacification: involving a whole lobe or multiple lobes
	
Other:	Other:
 - Interstitial pneumonia	 - All cavitory disease
 - Perihilar infiltrates	 - Expansile pneumonia
	 - Miliary TB
	 - TB bronchopneumonia

Glossary

Air bronchogram: The lung parenchyma (lung tissue) and the airways are normally filled with air – this means that they are black/dark on CXR and the smaller airways cannot be easily seen against the lung. When there is consolidation (air-space disease) of the lung tissue then that area of lung appears white/grey on CXR and the smaller airways appear as black/dark lines against this white/lighter background of the lung tissue – these are called air bronchograms and are a sign that there is consolidated lung.

Artefact: An artefact on a CXR image refers to an abnormal/unexpected shadow that is seen on the CXR that does not indicate an abnormality in the patient's body. An artefact is caused when something outside of the patient's body is included in the CXR frame (eg ECG electrodes which were left on the chest, a shirt button/buckle) and can confuse interpretation.

(tracheal) Buckling: This is a normal finding in young children. Because the trachea is more flexible in younger children and it is more difficult to ensure a good inspiratory film, it is not uncommon to see the trachea deviated to the right on the AP film (note that if the trachea is deviated to the left then this is always abnormal).

Cavity: A cavity is an air-filled space within the lung parenchyma (tissue). They are usually seen on CXR within an area of lung that is consolidated (appears lighter) so that the cavity appears black/dark and is usually round/oval in shape. Cavities may contain air-fluid levels which appear as a horizontal line within the cavity space, with fluid below the line (appearing light/white) and gas above the line (appearing dark/black).

Coalesced (lesions): When 2 or more lung lesions join together/overlap on the CXR they are described as being coalesced.

Concave: A concave shape is one which curves inwards (like the inside of a bowl).

Consolidation: This refers to the process where the alveoli (air-spaces) are filled with inflammatory fluid and the affected lung area thus appears whiter/lighter on CXR. On CXR consolidation appears as areas of dense/fluffy opacification (whiteness) involving a lobe (this is called ‘lobar consolidation’) or part of a lobe (this is called ‘segmental consolidation’) and there may be associated air bronchograms or pleural effusion. Bronchopneumonia refers to poorly defined, patchy areas of consolidation which may involve more than one lobe. The terms consolidation, air-space disease and alveolar opacification are often used interchangeably and refer to the same pathology and pattern on CXR.

Convex: A convex shape is one which curves outwards (like the outside of a circle).

Density: In the context of CXR interpretation density usually describes the body tissue through which the x-rays pass. Body tissue that is the most dense, such as bone, will appear white on CXR. Tissue that is medium density, such as the liver and the heart, will appear grey on CXR while tissue that is air-filled, such as the airways and the lungs, will appear black/darker on CXR. When areas of the lung are infected, inflammatory fluid replaces the air making the lung denser and more white/light on CXR than normal.

Erect: If a CXR is labelled as ‘erect’ it means the patient was standing when the CXR was taken.

Expansile (pneumonia): When an infective process in the lung results in an increase in the volume of the affected lobe/segment, then this is called an expansile pneumonia. On CXR the fissures of the affected lobe will bulge outwards and the expanding lobe may push other surrounding structures away and can cause shift of the mediastinum.

Expiration: Breathing out

Hyperlucency / Lucency: This is a very useful general term to use to describe what you see on a CXR. When there is an area in the lung that is blacker/darker than normal with decreased normal lung markings, it is called a lucency/hyperlucency and it means that there is more air (or less tissue) than normal. Hyperlucencies (or ‘an area of hyperlucency’) can be caused by several different pathologies, such as a lung cyst, a hyperinflated lobe or a pneumothorax.

Inspiration: Breathing in

Interstitial: The interstitium of the lung refers to the supporting tissue of the lung that is not directly involved in air exchange. When pathology in the lung involves the alveoli (air-spaces) it is called consolidation or air-space disease, and when pathology involves the interstitium it is called interstitial lung disease. On CXR interstitial infiltrates look like a combination of lines and dots (reticular, nodular or reticulonodular) and are usually more diffuse (widespread) than areas of consolidation.

Linear: A linear pattern is one which is arranged in a straight (or nearly straight) line.

Lordotic (view): For the normal AP/PA view the x-rays hit the chest wall perpendicular (at 90°) to the chest wall. For the lordotic CXR view the head and shoulders are tilted backwards (if patient is erect) or downwards (if patient is supine) so that the x-rays hit the chest wall at 45° and the clavicles do not obscure the lung tissue. In adults this view may be performed in order to see the lung apices more clearly. In children this view is usually taken in error due to technical difficulties with obtaining the CXR and the film may need to be repeated to allow for correct interpretation.

Lytic (lesions): This refers to a destructive process within a bone where an area of the bone (which is usually white/light) may appear darker.

Opacity: This is a very useful general term to describe what you see on a CXR. When an area of the lung has increased whiteness/lightness this is called an opacity. This indicates that there is less air and more inflammatory fluid/pus/blood/cells than normal. Opacities (or 'an opacification') can be caused by several different pathologies, such as consolidation, pleural effusion or a lung mass.

Patent (airways): If an airway is patent, this means that it is normal, open and air-filled, and is not compressed or narrowed.

Reticular: This refers to a CXR pattern that involves multiple straight (or curved) lines that are usually seen diffusely throughout the lung. This usually tells you that there is a pathology in the lung interstitium.

Reticulonodular: This refers to a CXR pattern where there are overlapping straight (or curved) lines as well as small dots (nodules). This pattern is usually seen diffusely throughout the lung and usually indicates a pathology in the interstitial part of the lung.

Silhouette sign: When two structures are in direct contact with each other you cannot see the border between them on the CXR – this is called the silhouette sign and it is used to localise lesions on the CXR. A good example is that an opacity in the right lung may obscure the border of the heart – this means that the opacity is in the right middle lobe (because this lobe is in direct contact with the heart).

Supine: If a CXR is labelled ‘supine’ it means the patient was lying down when the CXR was taken.

ABOUT THE INTERNATIONAL UNION AGAINST TUBERCULOSIS AND LUNG DISEASE (THE UNION)

The Union is a scientific, technical and membership organisation. Established in 1920, The Union strives to end suffering due to tuberculosis and lung diseases, old and new, by advancing better prevention and care. We seek to achieve this by the generation, dissemination and implementation of knowledge into policy and practice. We aim to ensure that no-one is left behind, people are treated equally and we have a focus on vulnerable and marginalised populations and communities.

A healthier world for all, free of tuberculosis and lung disease.

ISBN: 979-10-91287-32-6